

# Genital System

Gender genotype is inherited, but gender phenotype is a consequence of hormones released during embryonic development. Development of genitalia involves transitions through an indifferent stage in which gonads, genital ducts and external features are initially the same in both sexes. Thus, most genital anomalies involve some combination of intersex development and appearance.

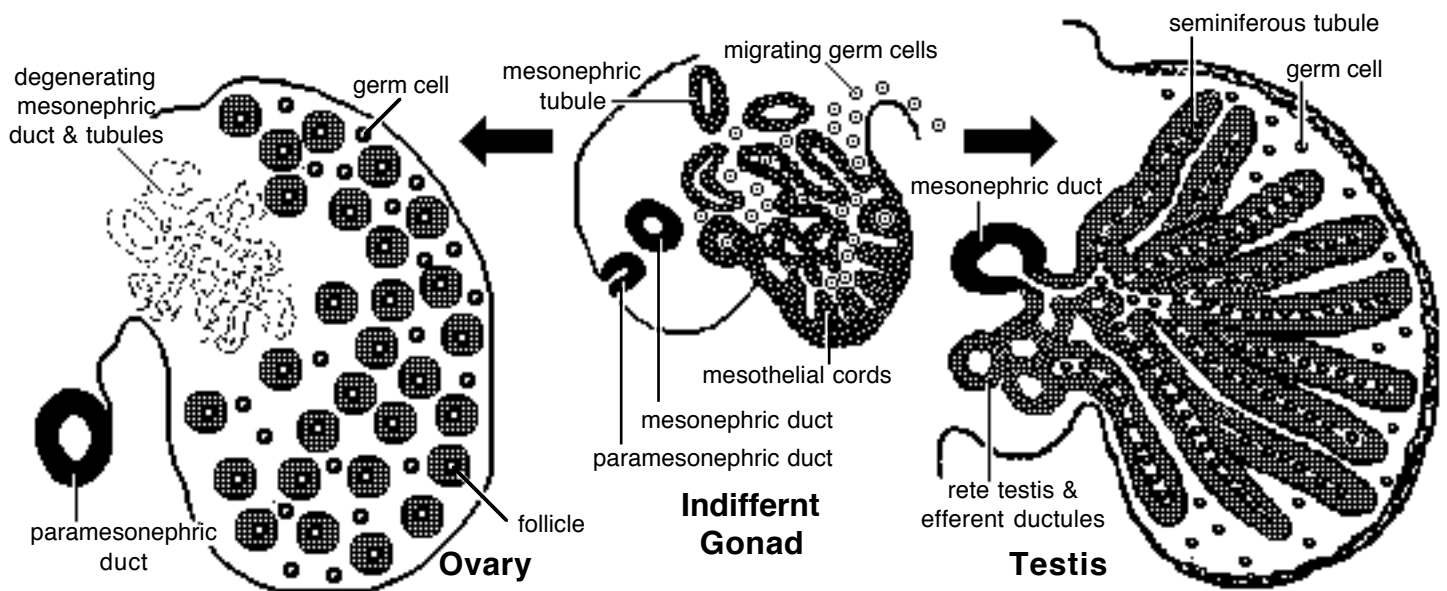
## Gonads

**Indifferent stage.** Each gonad originates from the *gonadal ridge*, a thickening of intermediate mesoderm and covering coelomic mesothelium that develops medial to the mesonephric kidney. The parenchyma of a gonad consists of germ cells and supporting cells:

- *supporting cells* are derived from invading coelomic mesothelial cells, augmented by cells from disintegrating mesonephric tubules. The supporting cells form cellular cords (gonadal cords) that radiate into gonadal ridge mesoderm;

- primordial *germ cells* arise from yolk sac endoderm. The cells migrate along the gut wall and gut mesentery to reach the gonadal ridge. Their arrival induces further gonadal development:

Germ cells proliferate and migrate inside gonadal cords so they are surrounded by supporting cells (germ cells that fail to enter a supporting cell cord undergo degeneration).



**Testis.** Gonadal cords hypertrophy and are called *seminiferous cords*. Germ cells within seminiferous cords differentiate into *spermatogonia* and become dormant. (Deep cellular cords that lack germ cells become tubules of the *rete testis*, located centrally in the testis). At puberty, seminiferous cords become canalized, forming seminiferous tubules, and spermatogonia initiate spermatogenesis.

Supporting cells that form walls of the seminiferous cords differentiate into *sustentacular (Sertoli) cells* which secrete inhibitory factors that suppress both spermatogenesis and female duct development. Supporting cells outside seminiferous cords become two populations of *interstitial cells*—one produces androgens immediately, the other population delays androgen production until sexual maturity. Androgens stimulate male genitalia development in the fetus and at puberty.

Coelomic mesothelium covering the testis becomes visceral peritoneum. Mesenchyme deep to the mesothelium proliferates and becomes the tunica albuginea layer of the testis.

**NOTE:** In ovaries, 90% of the germ cells fail to become incorporated into follicles; they complete meiosis and degenerate. To reduce germ cell degeneration, the onset of meiosis is delayed in embryos of species having longer gestations.

# GENDER

- **Genotypic gender:** determined by genes
  - XX = female
  - XY = male
- **Phenotypic gender:** determined by hormones
  - body parts
  - physiology

XY → testis { testosterone  
inhibiting hormone

In the absence of testicular hormones  
a female develops, by default.

*Both genders are the same at the start.  
They develop from a common indifferent stage.*

# Genital System

Gender genotype is inherited, but gender phenotype is a consequence of hormones released during embryonic development. Development of genitalia involves transitions through an indifferent stage in which gonads, genital ducts and external features are initially the same in both sexes. Thus, most genital anomalies involve some combination of intersex development and appearance.

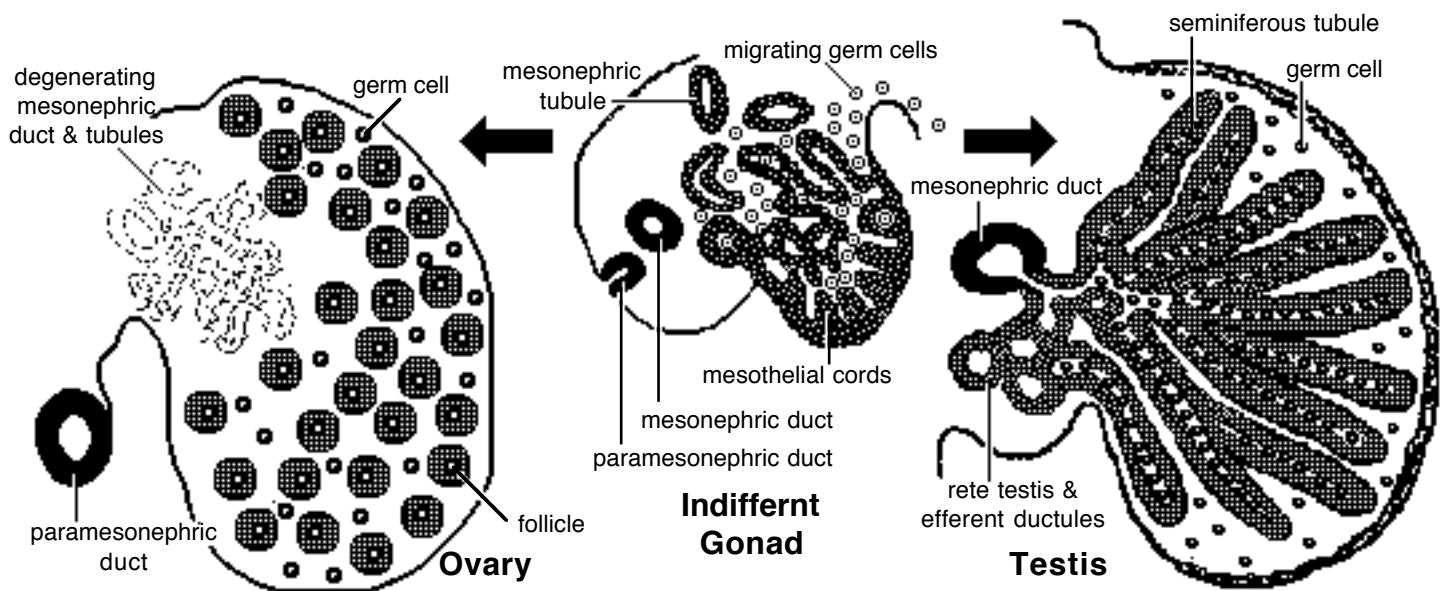
## Gonads

**Indifferent stage.** Each gonad originates from the *gonadal ridge*, a thickening of intermediate mesoderm and covering coelomic mesothelium that develops medial to the mesonephric kidney. The parenchyma of a gonad consists of germ cells and supporting cells:

- *supporting cells* are derived from invading coelomic mesothelial cells, augmented by cells from disintegrating mesonephric tubules. The supporting cells form cellular cords (gonadal cords) that radiate into gonadal ridge mesoderm;

- primordial *germ cells* arise from yolk sac endoderm. The cells migrate along the gut wall and gut mesentery to reach the gonadal ridge. Their arrival induces further gonadal development:

Germ cells proliferate and migrate inside gonadal cords so they are surrounded by supporting cells (germ cells that fail to enter a supporting cell cord undergo degeneration).

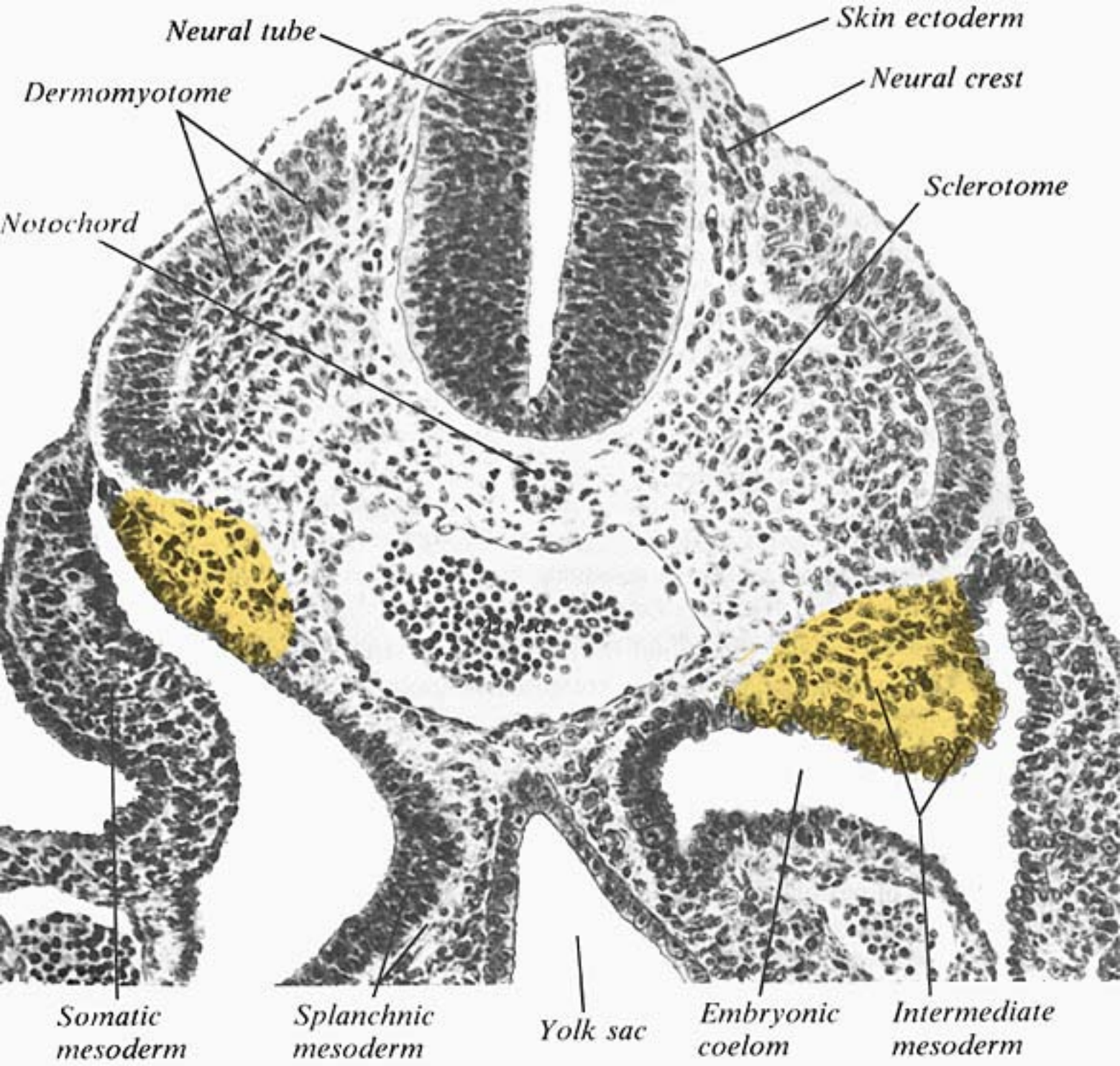


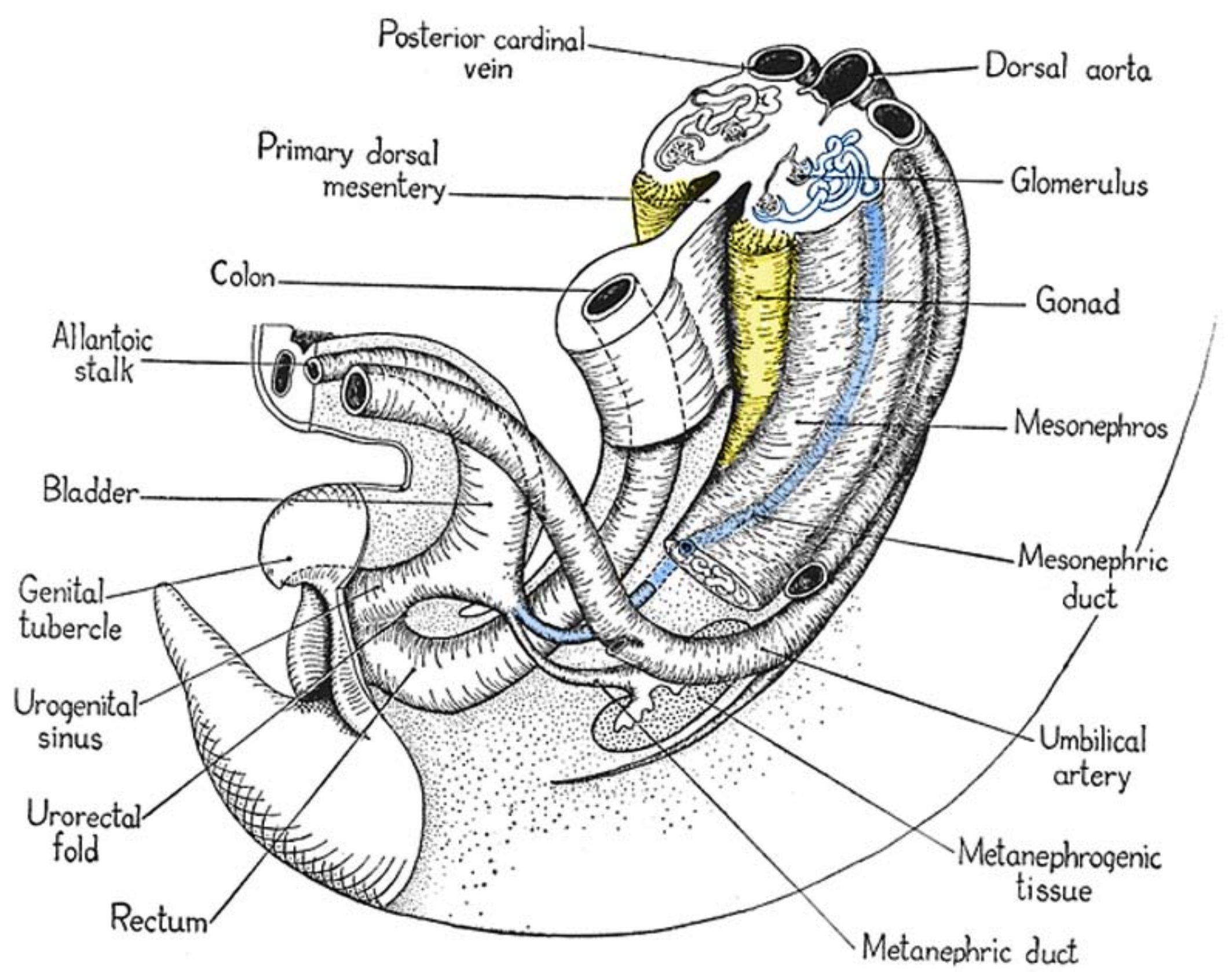
**Testis.** Gonadal cords hypertrophy and are called *seminiferous cords*. Germ cells within seminiferous cords differentiate into *spermatogonia* and become dormant. (Deep cellular cords that lack germ cells become tubules of the *rete testis*, located centrally in the testis). At puberty, seminiferous cords become canalized, forming seminiferous tubules, and spermatogonia initiate spermatogenesis.

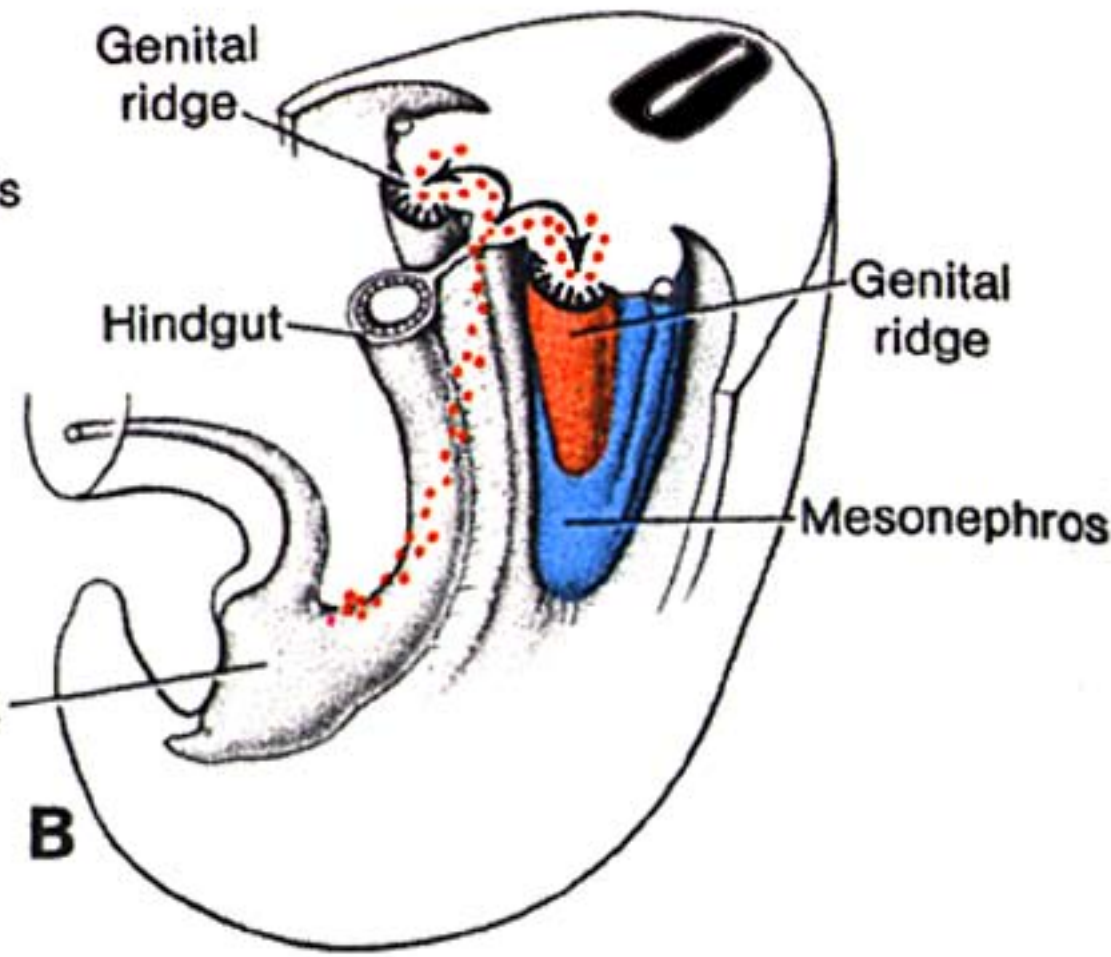
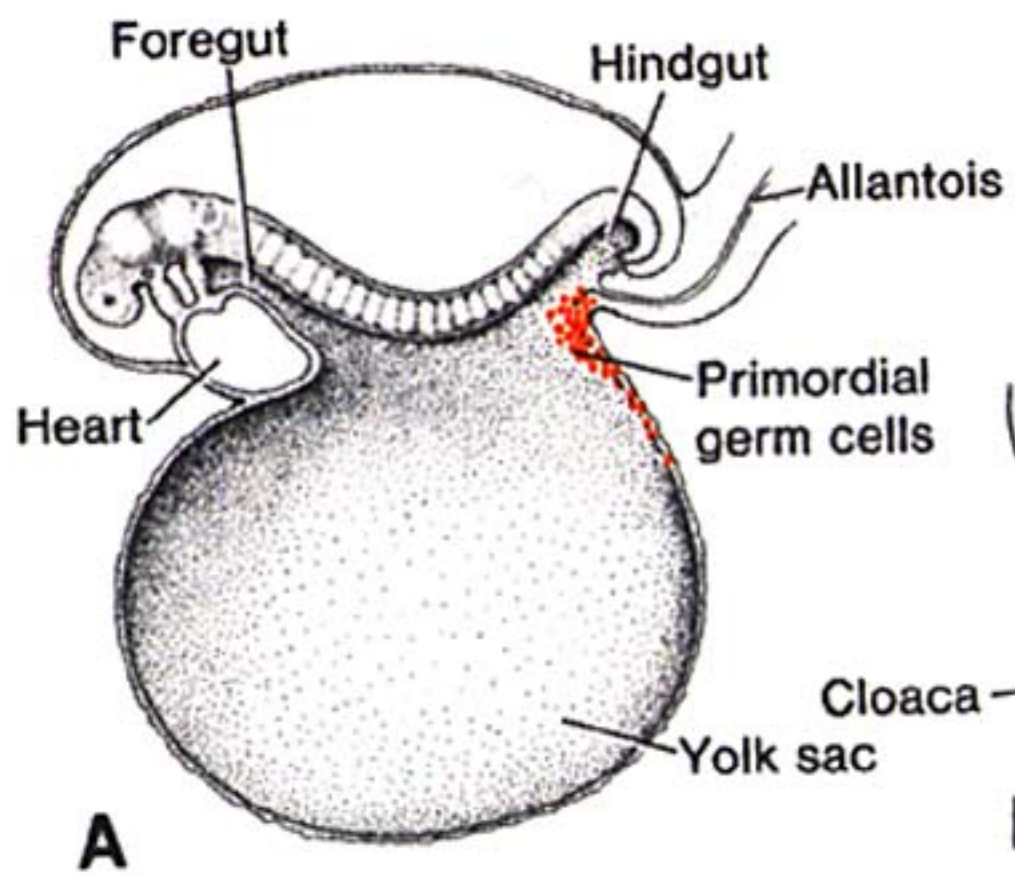
Supporting cells that form walls of the seminiferous cords differentiate into *sustentacular (Sertoli) cells* which secrete inhibitory factors that suppress both spermatogenesis and female duct development. Supporting cells outside seminiferous cords become two populations of *interstitial cells*—one produces androgens immediately, the other population delays androgen production until sexual maturity. Androgens stimulate male genitalia development in the fetus and at puberty.

Coelomic mesothelium covering the testis becomes visceral peritoneum. Mesenchyme deep to the mesothelium proliferates and becomes the tunica albuginea layer of the testis.

**NOTE:** In ovaries, 90% of the germ cells fail to become incorporated into follicles; they complete meiosis and degenerate. To reduce germ cell degeneration, the onset of meiosis is delayed in embryos of species having longer gestations.







# Genital System

Gender genotype is inherited, but gender phenotype is a consequence of hormones released during embryonic development. Development of genitalia involves transitions through an indifferent stage in which gonads, genital ducts and external features are initially the same in both sexes. Thus, most genital anomalies involve some combination of intersex development and appearance.

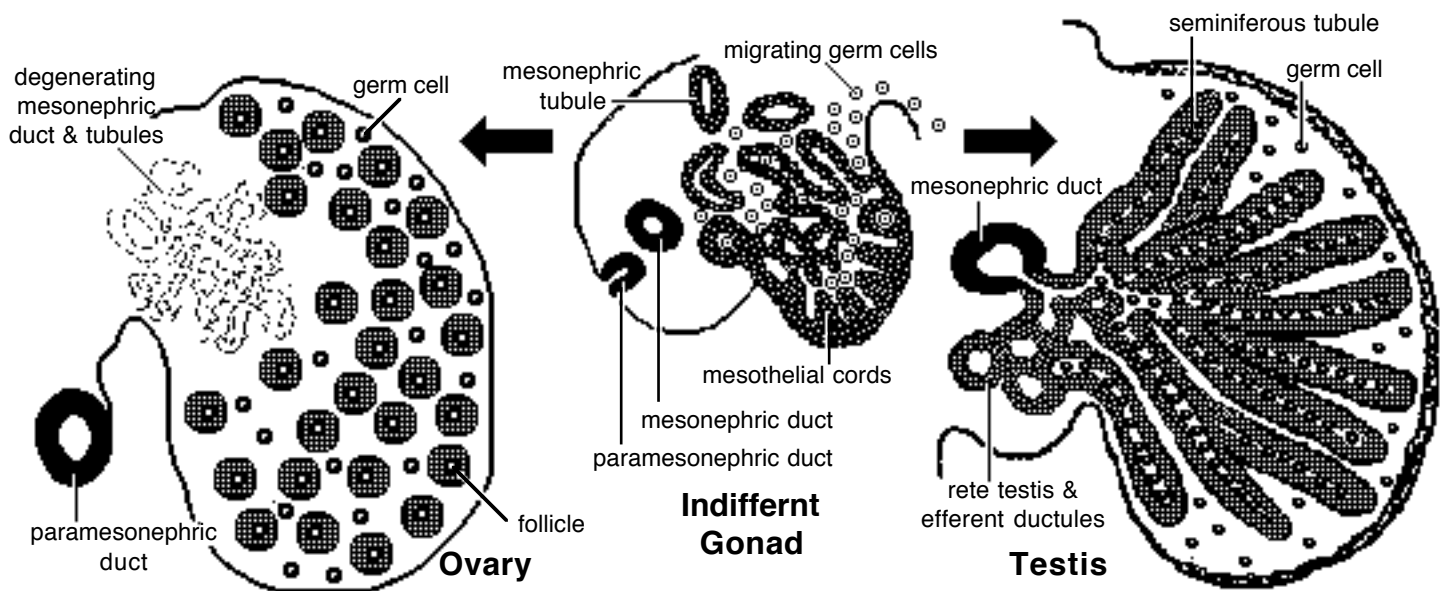
## Gonads

**Indifferent stage.** Each gonad originates from the *gonadal ridge*, a thickening of intermediate mesoderm and covering coelomic mesothelium that develops medial to the mesonephric kidney. The parenchyma of a gonad consists of germ cells and supporting cells:

- *supporting cells* are derived from invading coelomic mesothelial cells, augmented by cells from disintegrating mesonephric tubules. The supporting cells form cellular cords (gonadal cords) that radiate into gonadal ridge mesoderm;

- primordial *germ cells* arise from yolk sac endoderm. The cells migrate along the gut wall and gut mesentery to reach the gonadal ridge. Their arrival induces further gonadal development:

Germ cells proliferate and migrate inside gonadal cords so they are surrounded by supporting cells (germ cells that fail to enter a supporting cell cord undergo degeneration).



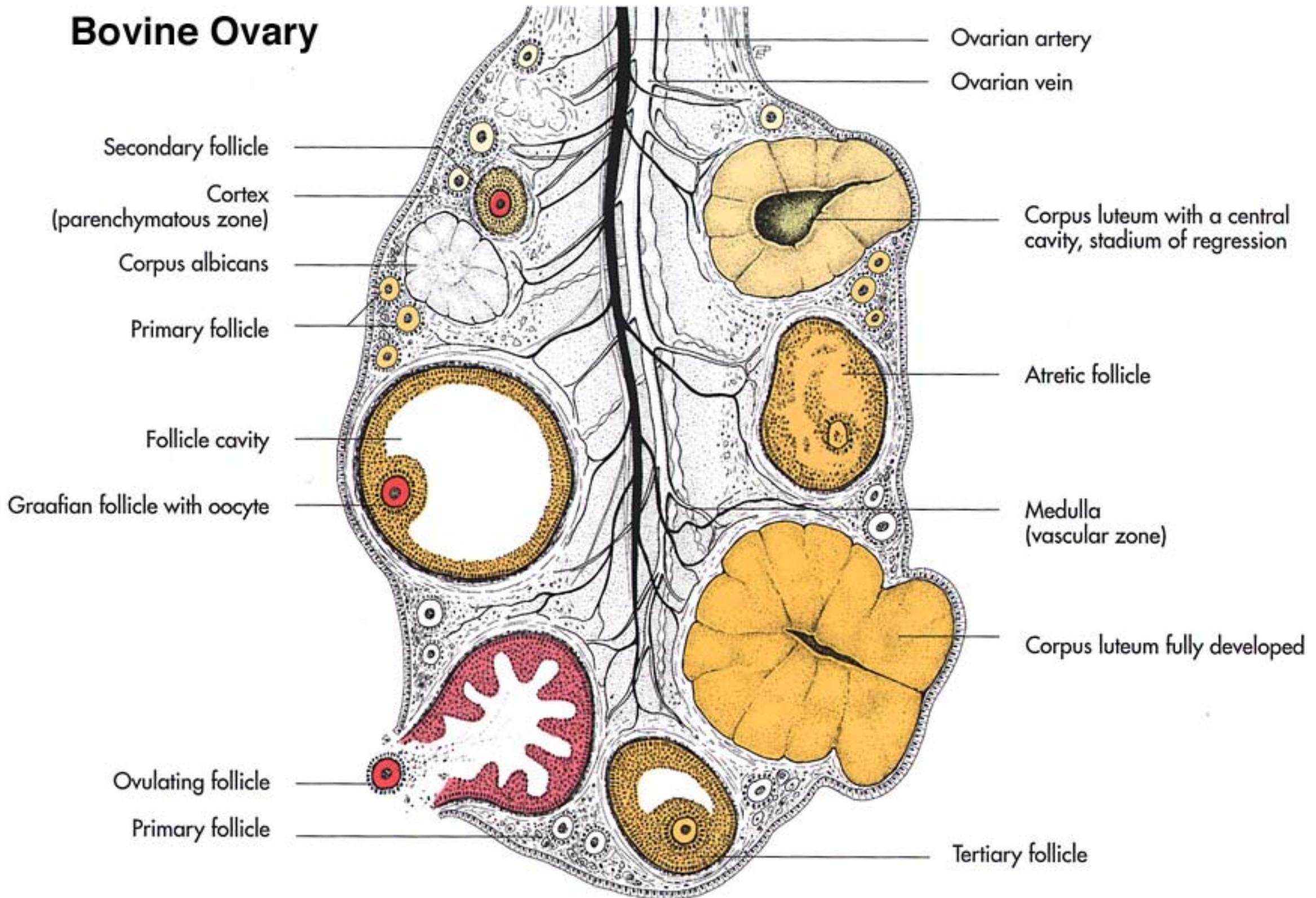
**Testis.** Gonadal cords hypertrophy and are called *seminiferous cords*. Germ cells within seminiferous cords differentiate into *spermatogonia* and become dormant. (Deep cellular cords that lack germ cells become tubules of the *rete testis*, located centrally in the testis). At puberty, seminiferous cords become canalized, forming seminiferous tubules, and spermatogonia initiate spermatogenesis.

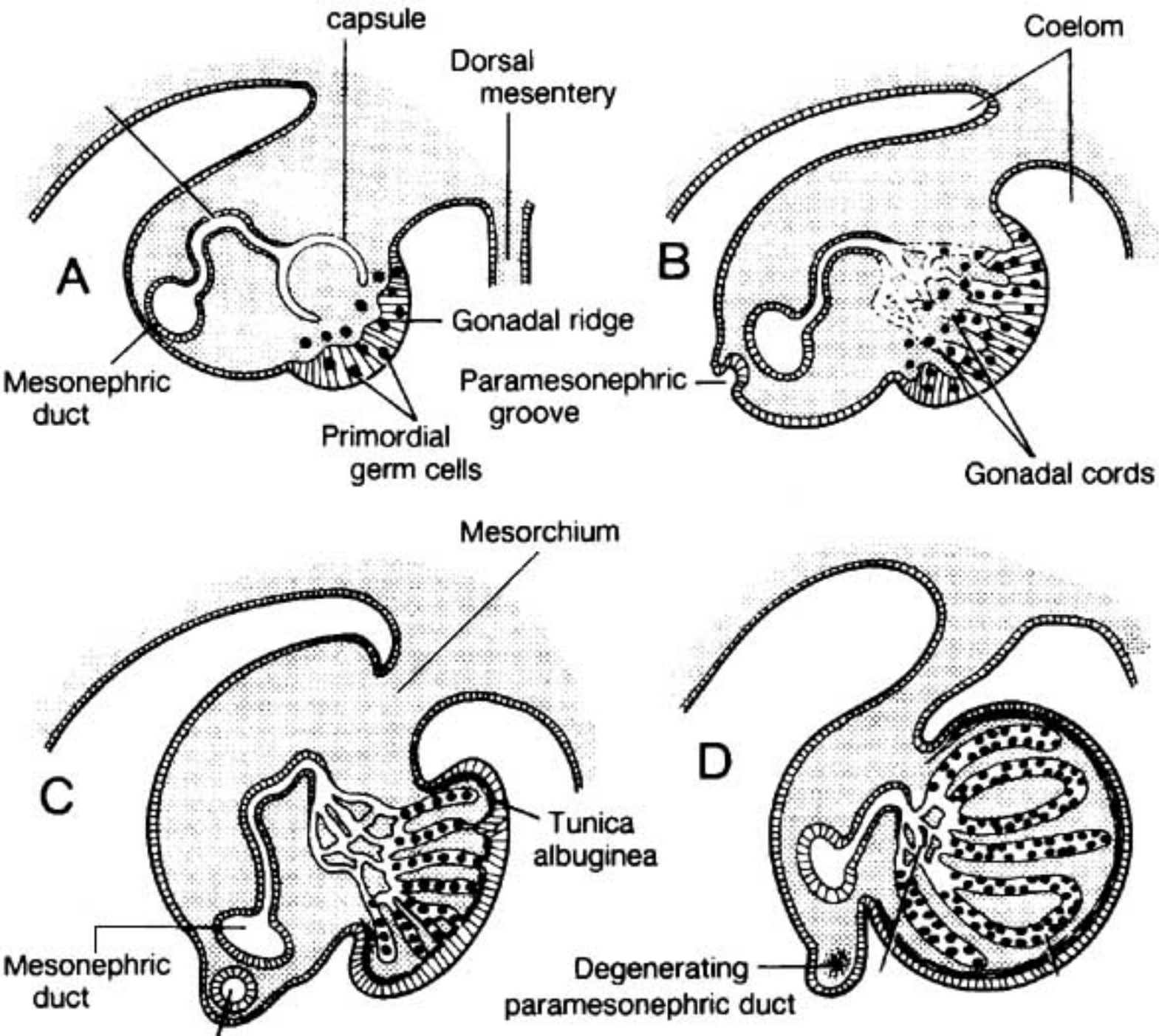
Supporting cells that form walls of the seminiferous cords differentiate into *sustentacular (Sertoli) cells* which secrete inhibitory factors that suppress both spermatogenesis and female duct development. Supporting cells outside seminiferous cords become two populations of *interstitial cells*—one produces androgens immediately, the other population delays androgen production until sexual maturity. Androgens stimulate male genitalia development in the fetus and at puberty.

Coelomic mesothelium covering the testis becomes visceral peritoneum. Mesenchyme deep to the mesothelium proliferates and becomes the tunica albuginea layer of the testis.

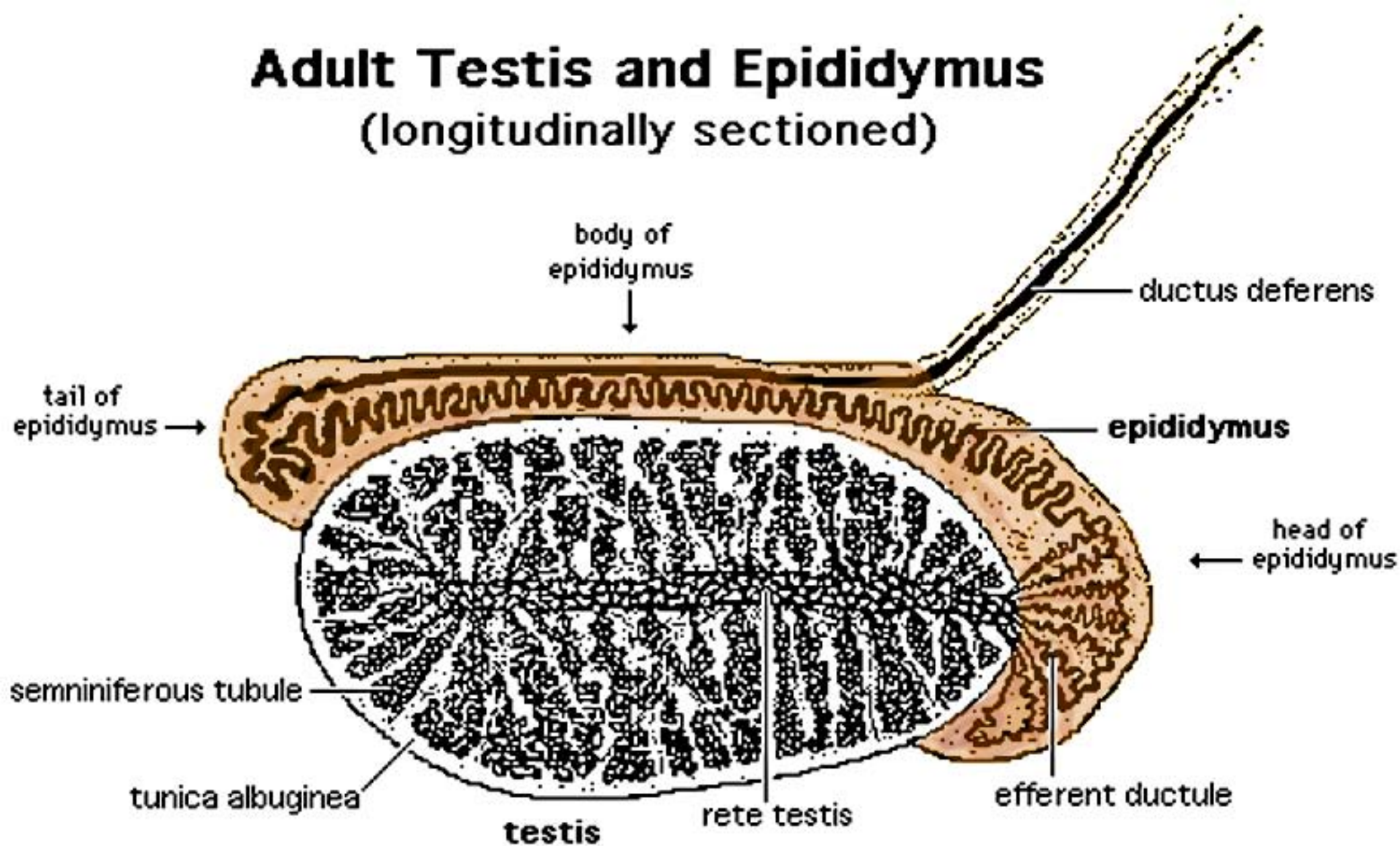
**NOTE:** In ovaries, 90% of the germ cells fail to become incorporated into follicles; they complete meiosis and degenerate. To reduce germ cell degeneration, the onset of meiosis is delayed in embryos of species having longer gestations.

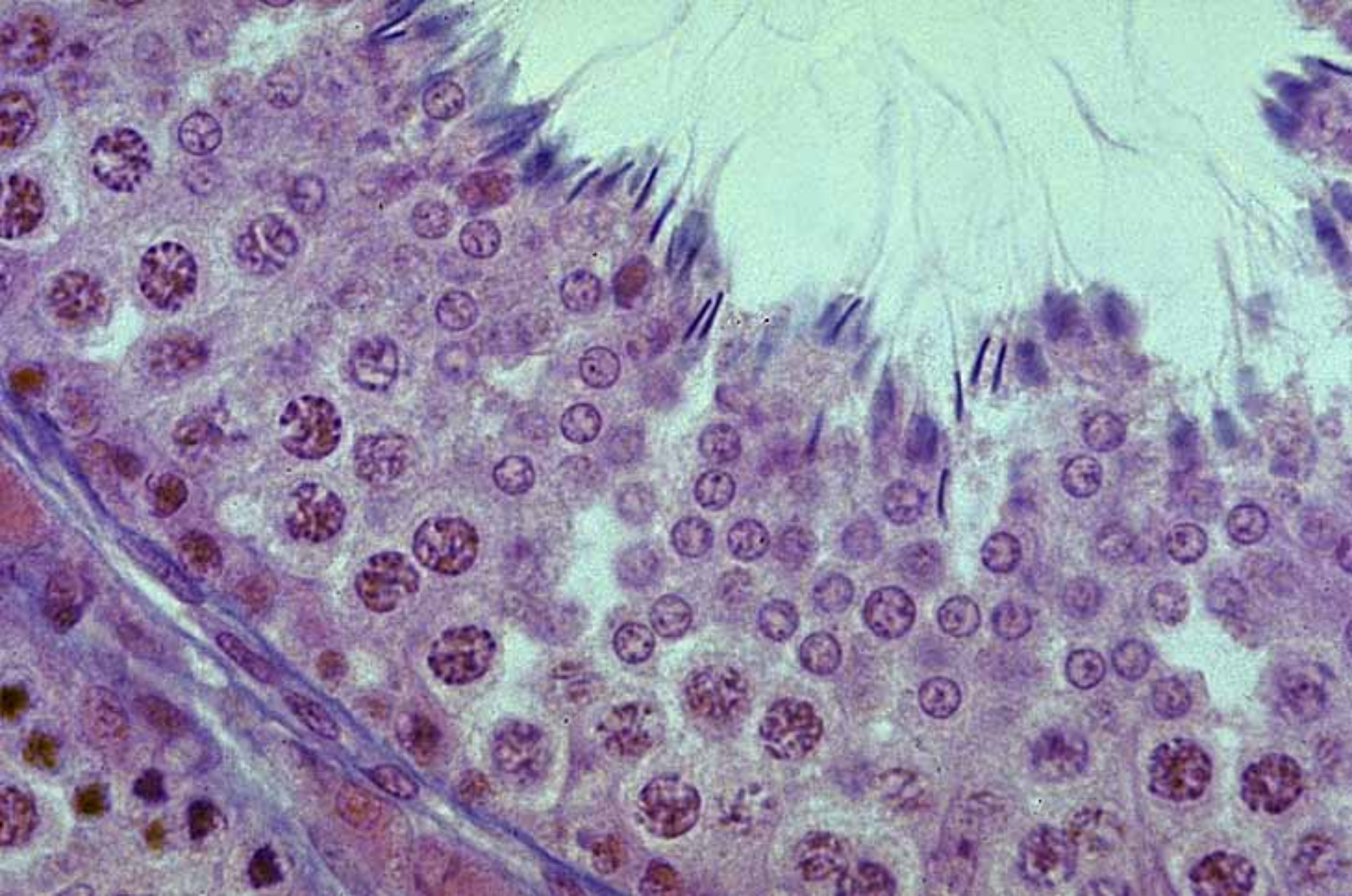
# Bovine Ovary





# Adult Testis and Epididymus (longitudinally sectioned)





**Ovary.** The cellular cords that contain germ cells undergo reorganization so that individual germ cells become isolated, each surrounded by a sphere of flat supporting cells—forming *primordial follicles*. Follicle and germ cell proliferation is completed before birth. Germ cells (oogonia) differentiate into primary oocytes that commence meiosis, but remain in prophase of Meiosis I until ovulation (following puberty). The lifetime allotment of primary oocytes is present in the neonatal ovary.

## Genital ducts, accessory glands, and ligaments

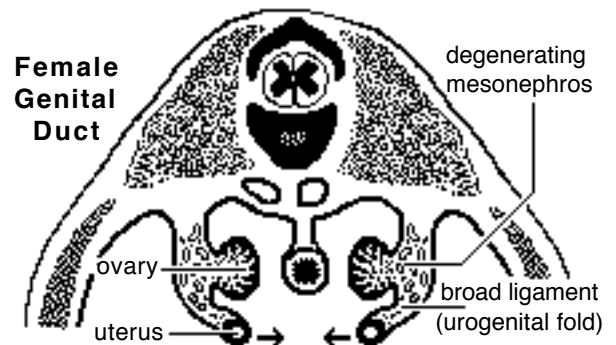
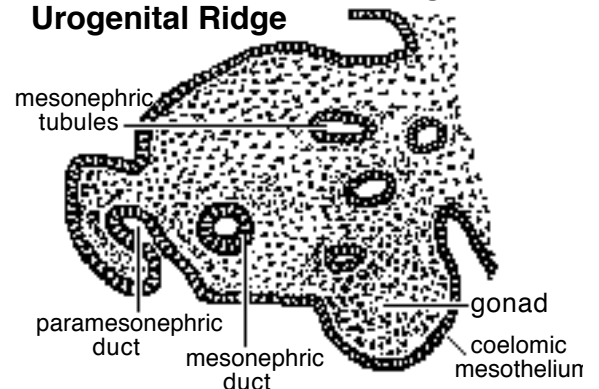
**Indifferent stage.** Both sexes have male (mesonephric) and female (paramesonephric) genital ducts and a urogenital sinus. The mesonephric (Wolffian) duct persists after the mesonephros disintegrates. A paramesonephric (Mullerian) duct develops along the ventrolateral coelomic surface of the mesonephros. It begins as a groove. The edges of the groove merge to form a core of cells that subsequently canalize and elongate.

Which duct system develops, is determined by testicular hormones. Male duct development requires testosterone (produced by interstitial cells). The testis (sustentacular cells) also releases an inhibitory hormone that suppresses female duct development.

**Female.** In the absence of testosterone, mesonephric ducts fail to develop (histologic remnants may be found in the wall of the vestibule).

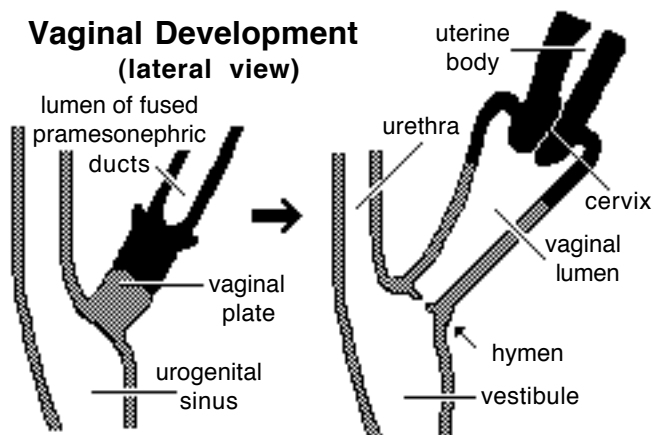
The cranial region of each paramesonephric duct remains open and forms the future *uterine tube*. Caudal to the level of the inguinal fold (gubernaculum), each paramesonephric duct becomes a *uterine horn*. Further caudally, the bilateral paramesonephric ducts shift medially and fuse into a single tube that ends blindly in contact with the urogenital sinus. The fused ducts become *uterine body*, *uterine cervix*, and the cranial third of the vagina.

### Transverse Section through Urogenital Ridge

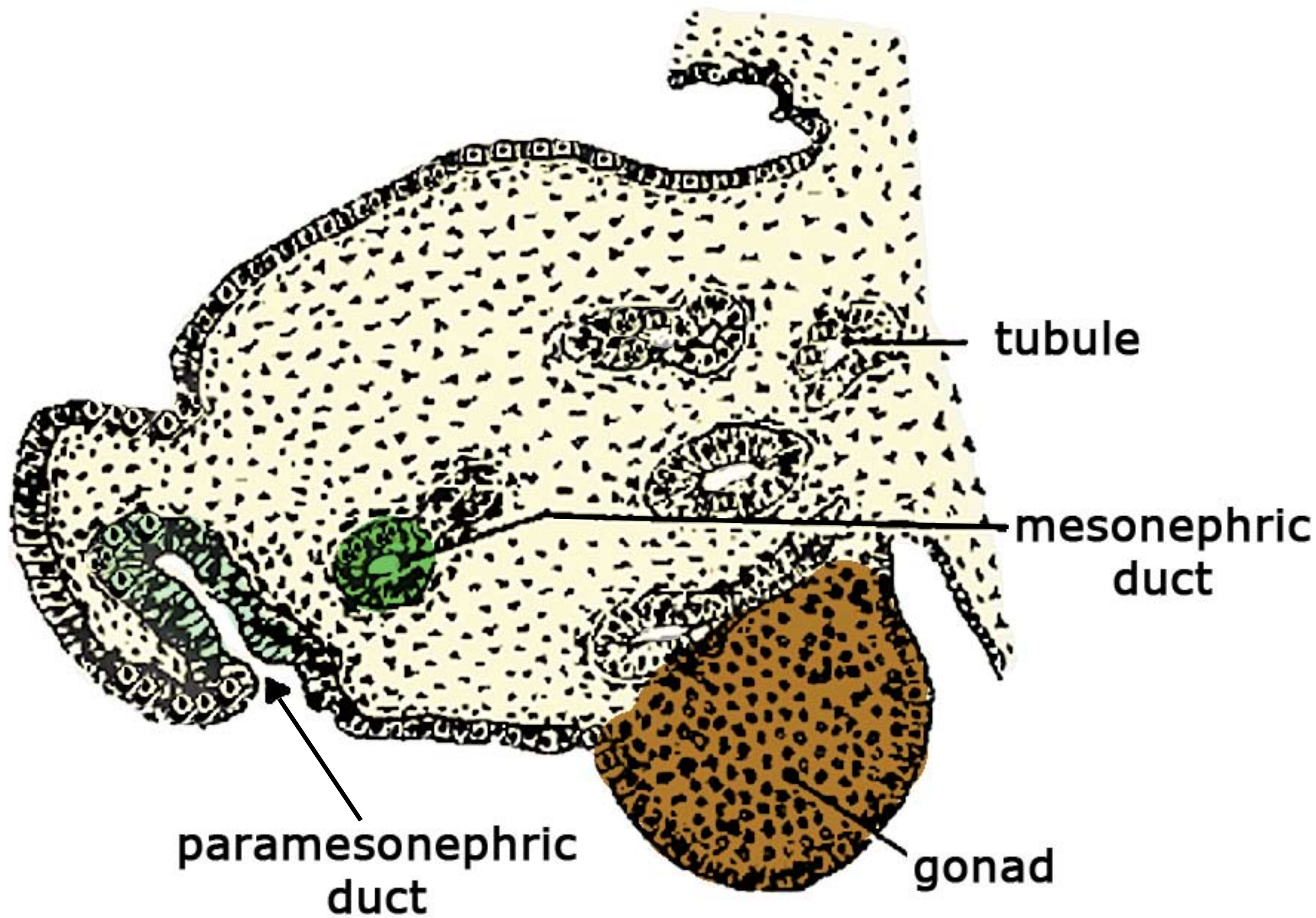


**NOTE:** The degree of paramesonephric duct fusion is species dependent. Among domestic mammals, fusion is greatest in the horse and least in carnivores. In primates (women) fusion normally produces a uterine body without horns. In contrast, rodents and the rabbit have a double uterus (two cervixes enter a single vagina). Monotremes and many marsupials have a double vagina (no fusion at all).

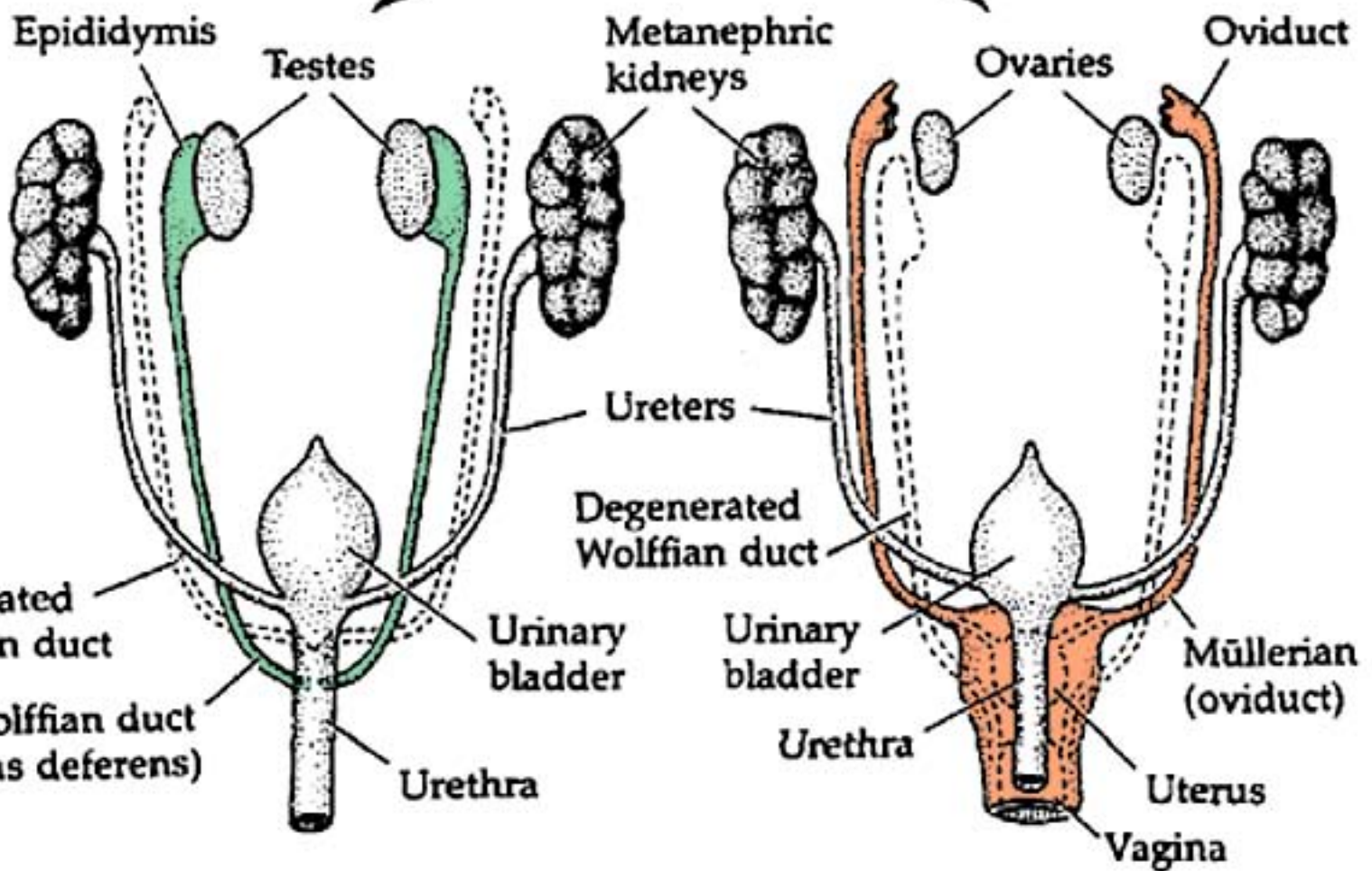
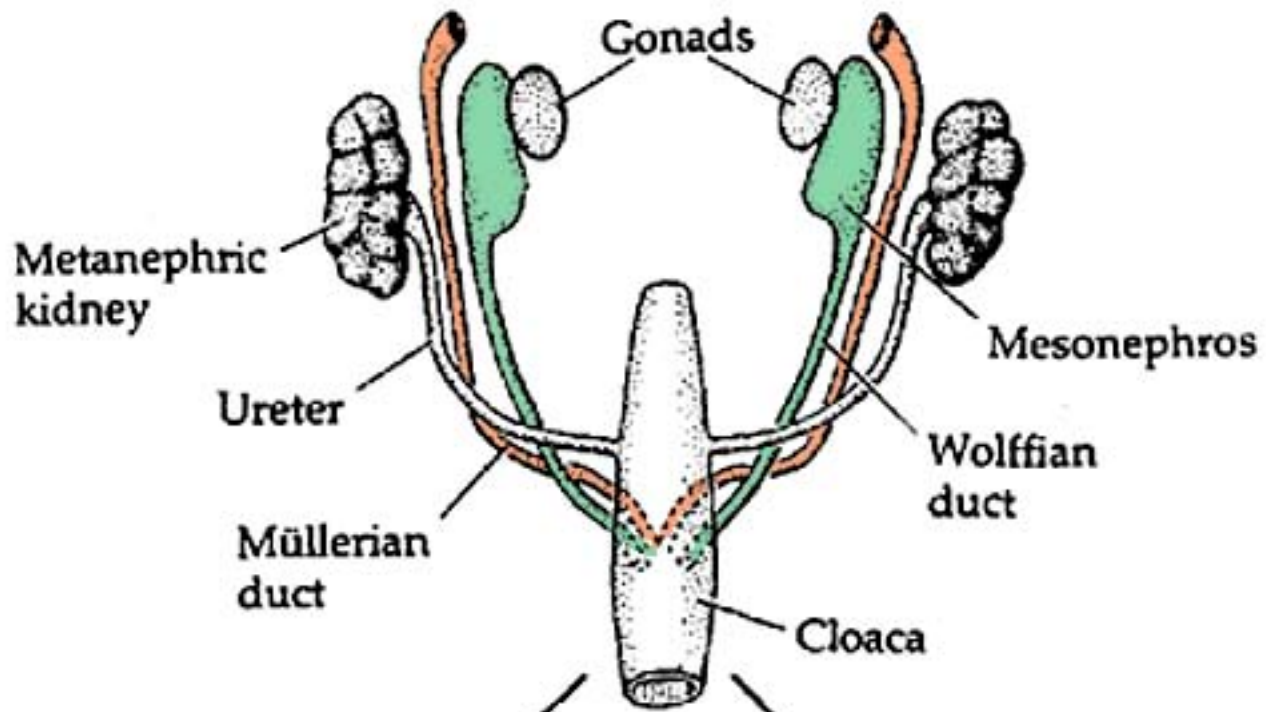
### Vaginal Development (lateral view)



The *vagina* has a dual origin. The cranial one-third comes from fused paramesonephric ducts. The caudal two-thirds comes from the vaginal plate, a solid tubercle that grows outward from the urogenital sinus at the site of contact between the urogenital sinus and the fused paramesonephric ducts. Degeneration of the center of the solid tubercle creates the vaginal lumen. A hymen may persist where the vagina joins urogenital sinus. The urogenital sinus forms the *vestibule*.

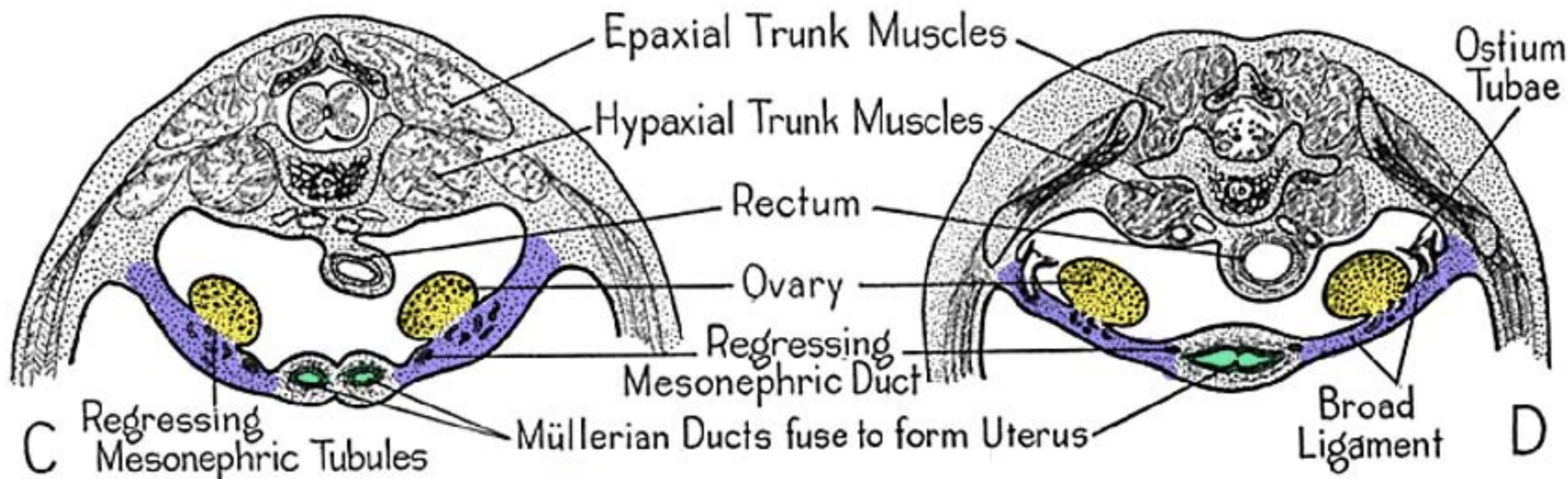
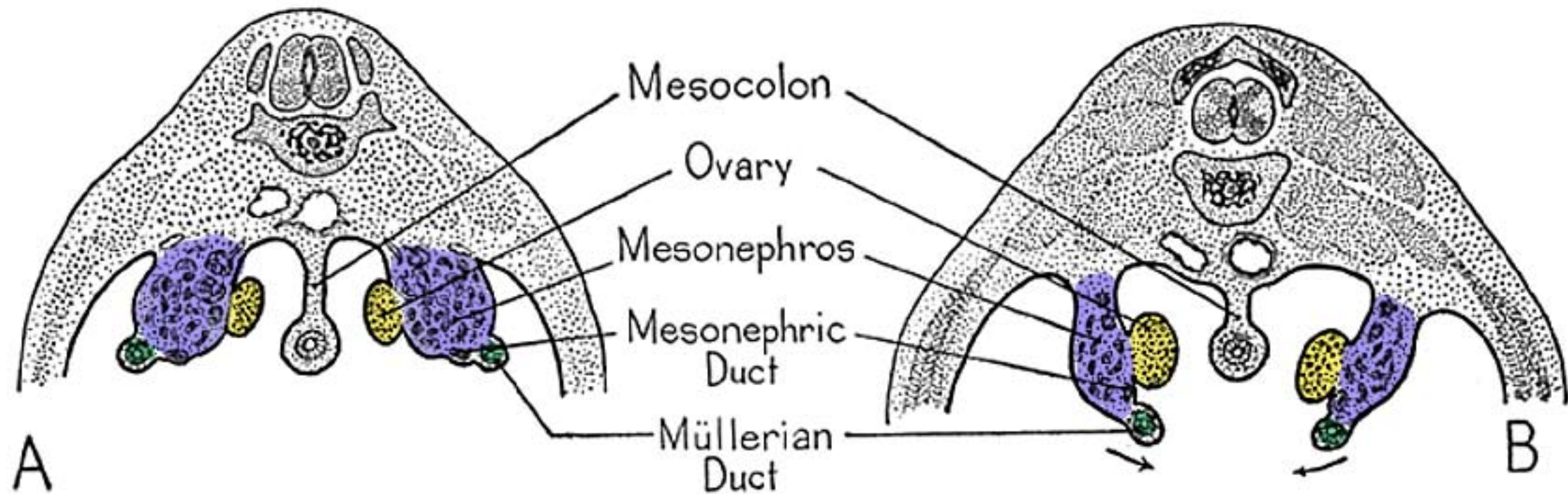


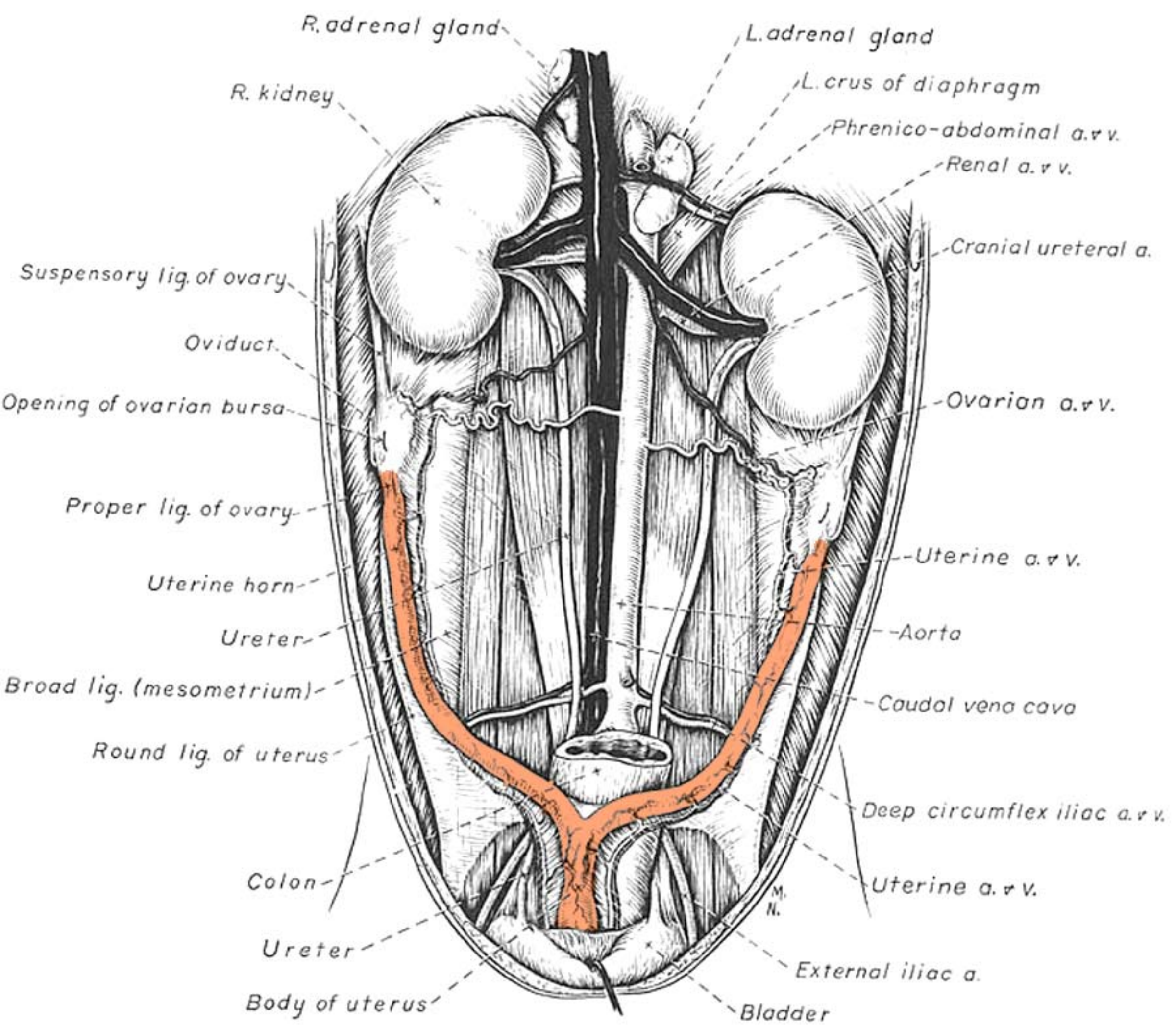
(A) SEXUALLY INDIFFERENT

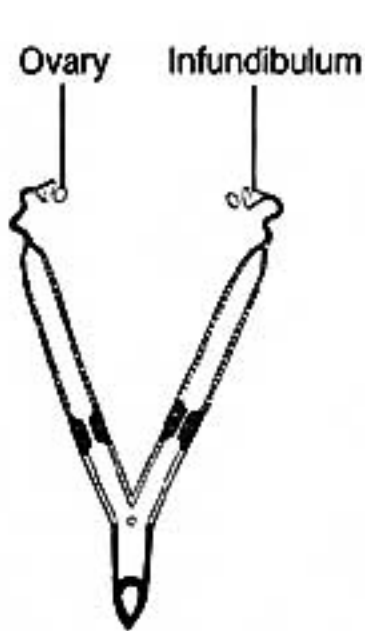


(B) MALE

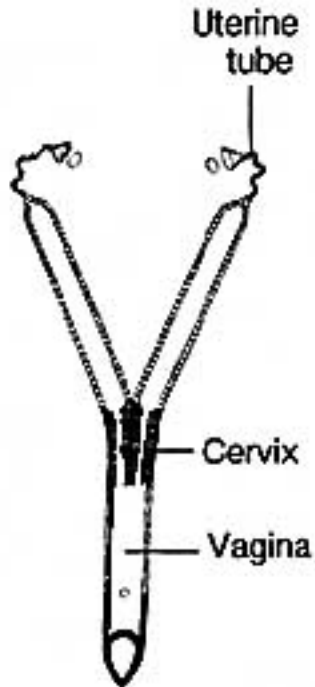(C) FEMALE



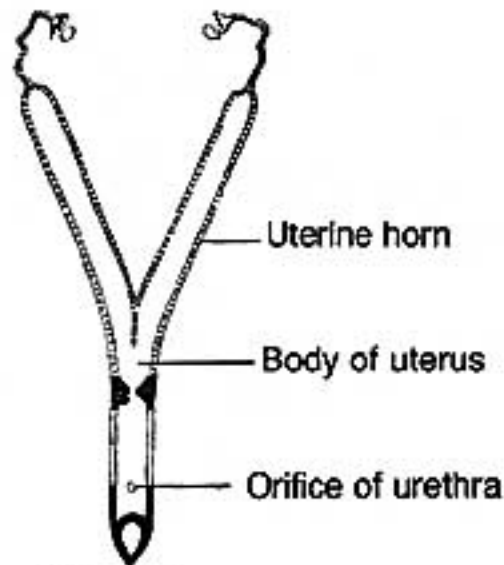




**A** MONOTREME



**B** RODENT, RABBIT



**C** DOG



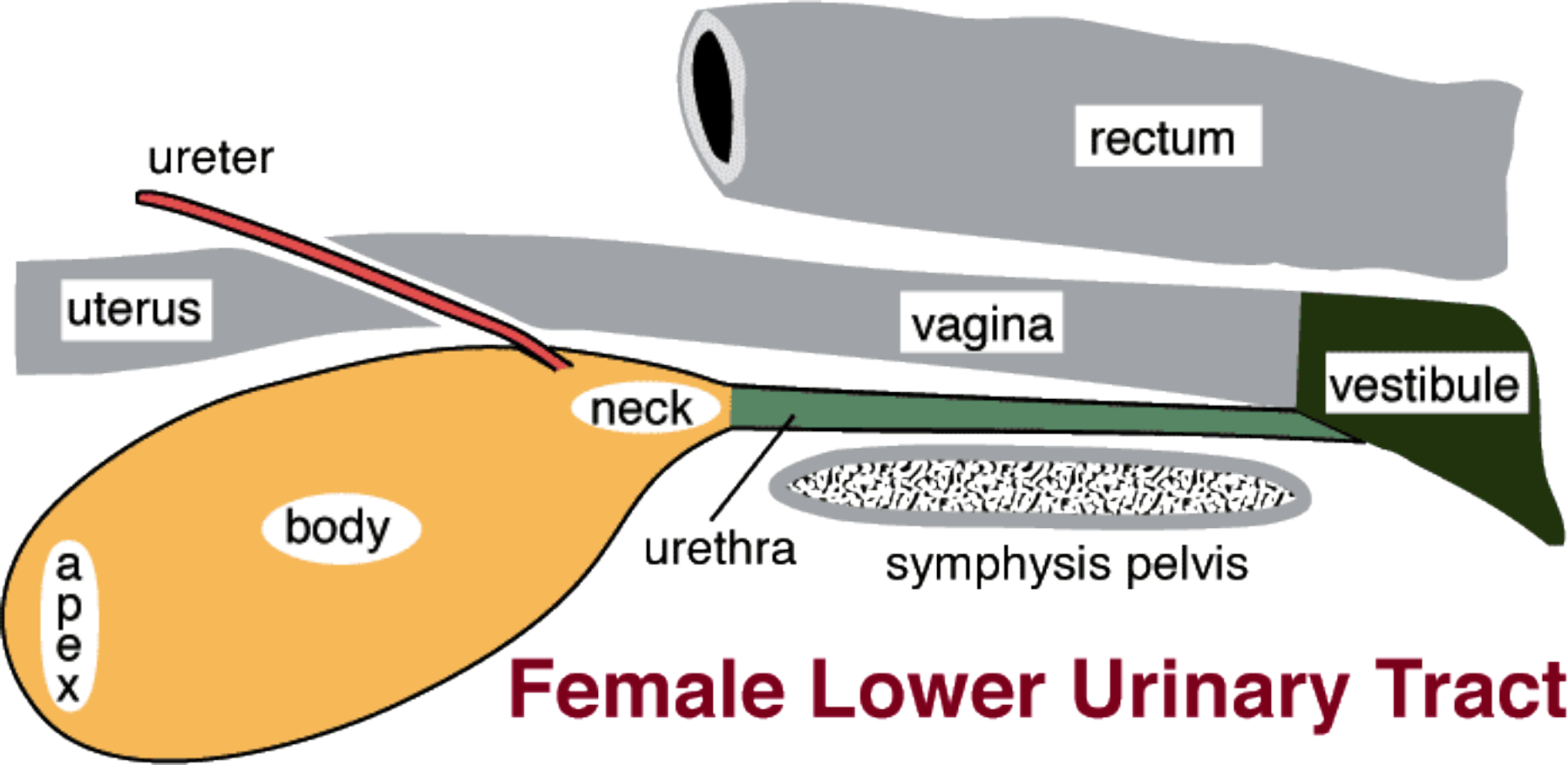
**D** PIG

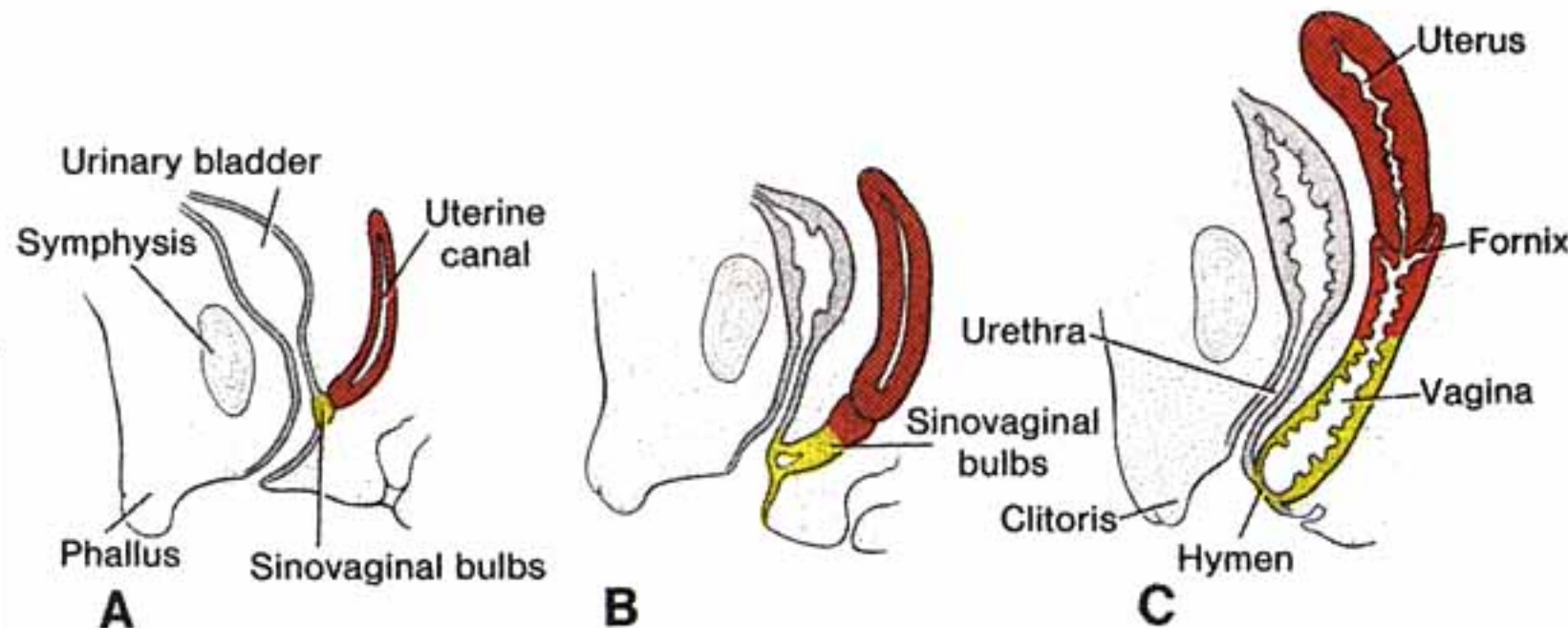
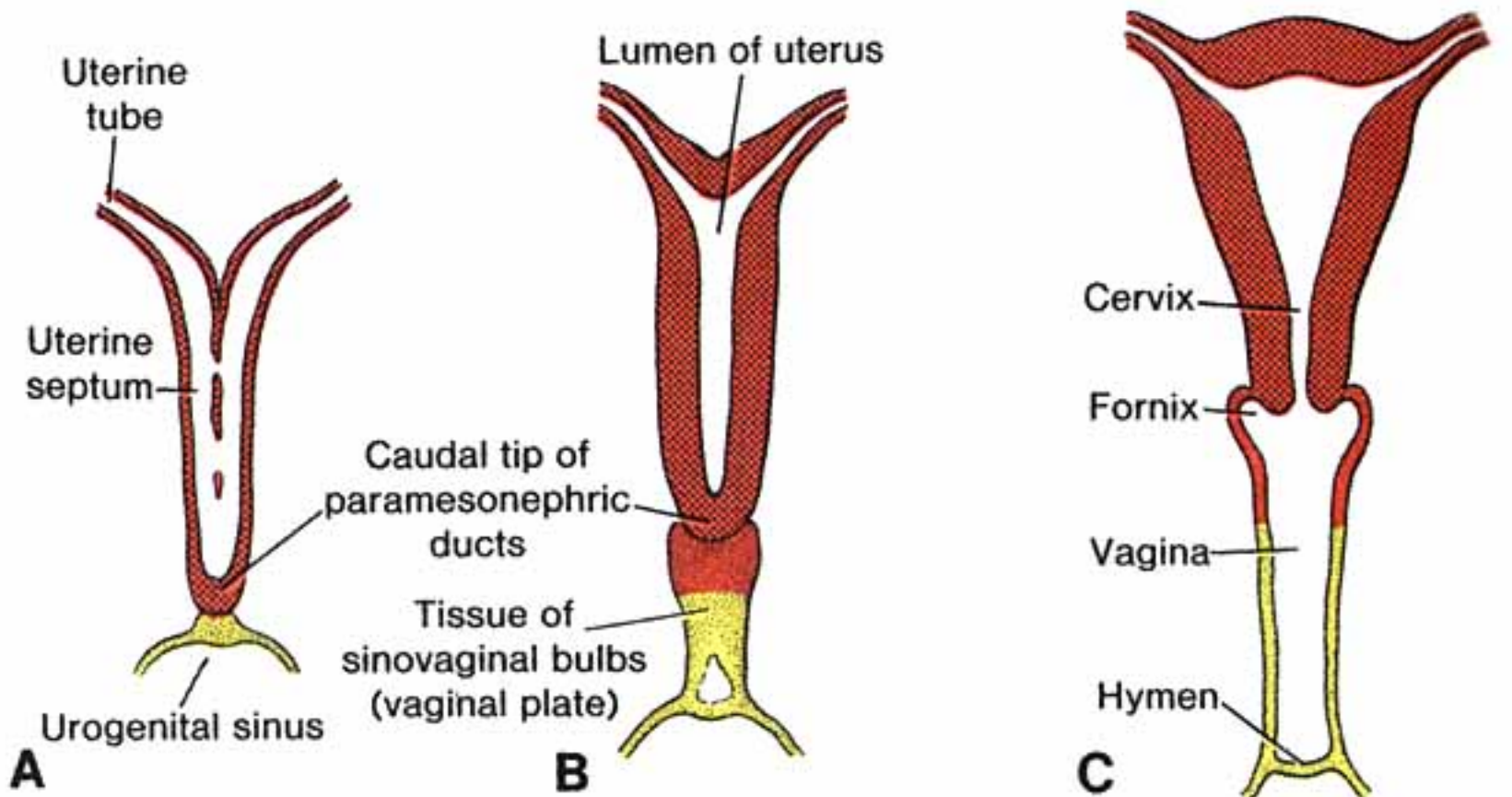


**E** COW



**F** HORSE



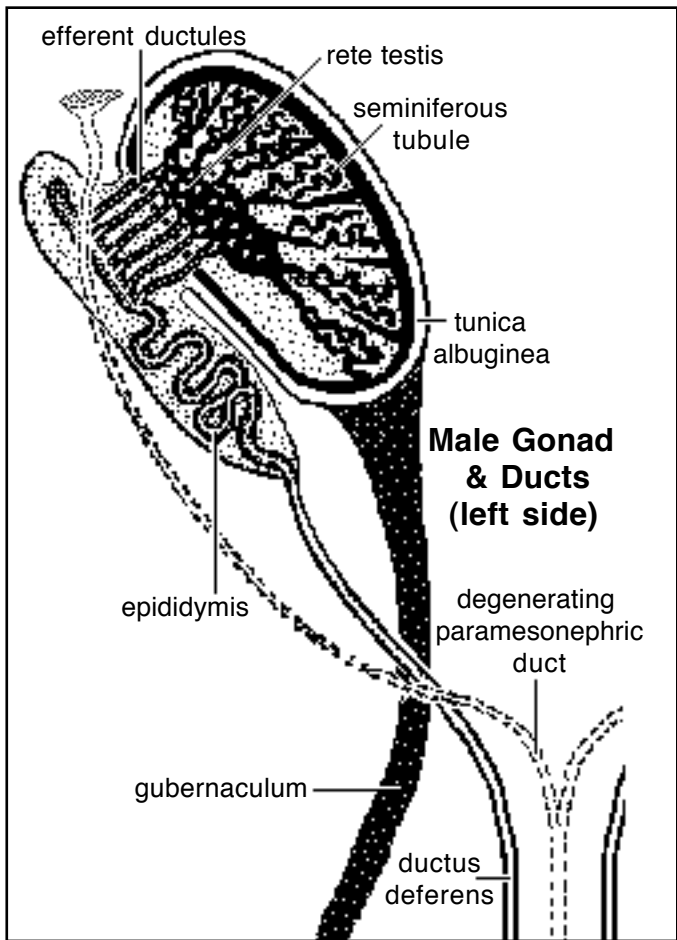


**Male.** Paramesonephric ducts regress due to an inhibitory hormone produced by the testis (sustentacular cells). Duct remnants are often evident in the adult male horse (uterus masculinus).

About a dozen mesonephric tubules are converted to *efferent ductules* (they already communicate with the mesonephric duct but must establish communication with the rete testis). The cranial region of the mesonephric duct undergoes extensive elongation and coiling to become the *epididymis*; the remainder of the duct enlarges and becomes *ductus deferens*. The mesonephric duct empties into the urogenital sinus, which becomes *pelvic* and *penile urethra*.

**Glands.** Prostate and bulbourethral glands develop in typical gland fashion from evaginations of urogenital sinus endoderm. (Vestibular glands are female homologues of male bulbourethral glands.)

Each vesicular gland (seminal vesicle) arises as an epithelial evagination from the caudal region of the mesonephric duct (mesoderm). Gland smooth muscle comes from surrounding mesenchyme.



**Genital Ligaments.** When the mesonephros degenerates, it leaves behind a genital fold that suspends the gonad and genital duct system. The fold becomes male / female genital ligaments.

In females, the genital fold becomes: *suspensory ligament of the ovary*, *mesovarium*, *mesosalpinx*, and the *mesometrium*. (The caudal part of the mesometrium is formed by the tissue “shelf” that accompanies each paramesonephric duct when it shifts medially to fuse with its counterpart.)

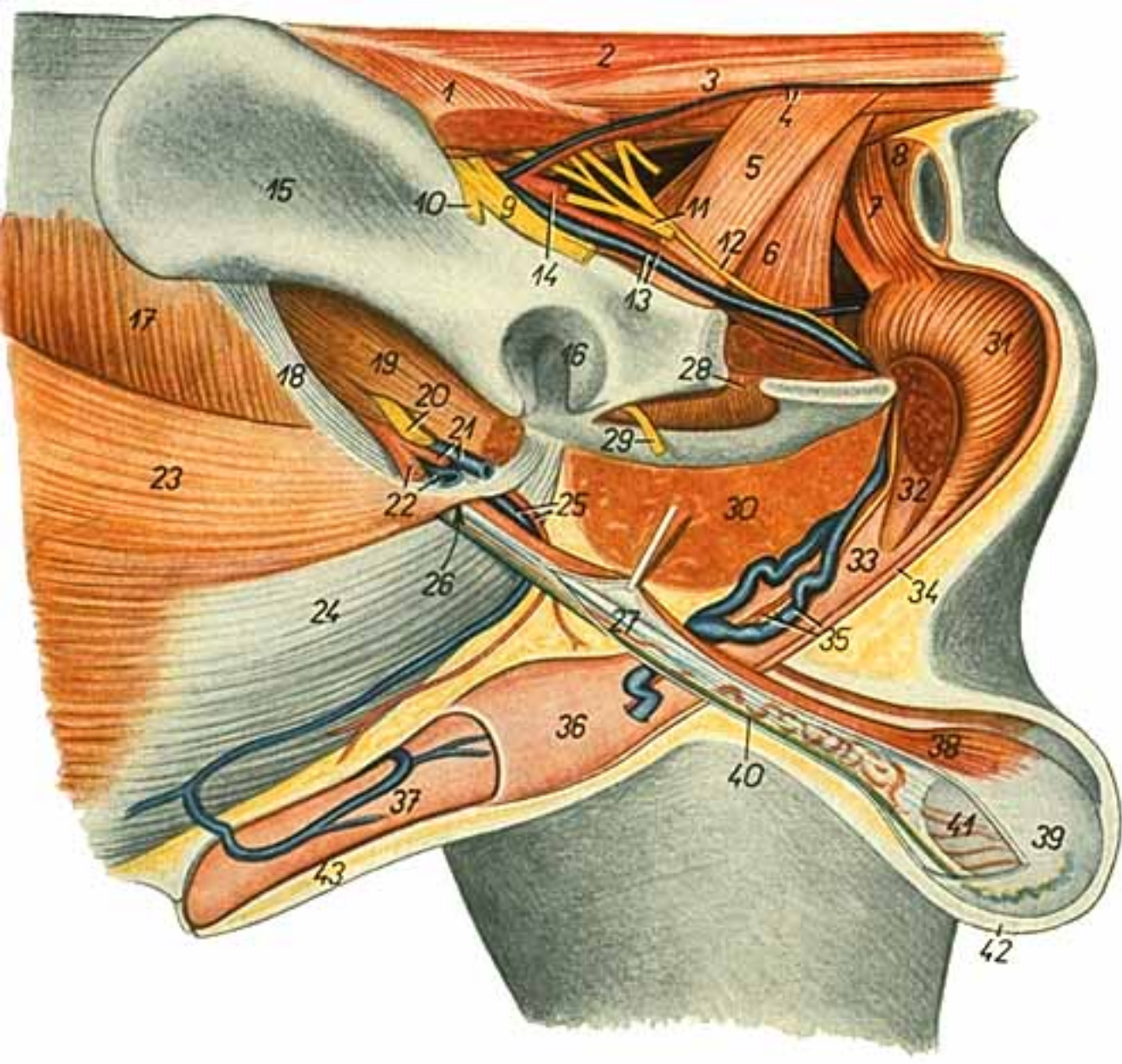
In males, the genital fold becomes *mesorchium* and *mesoductus deferens*.

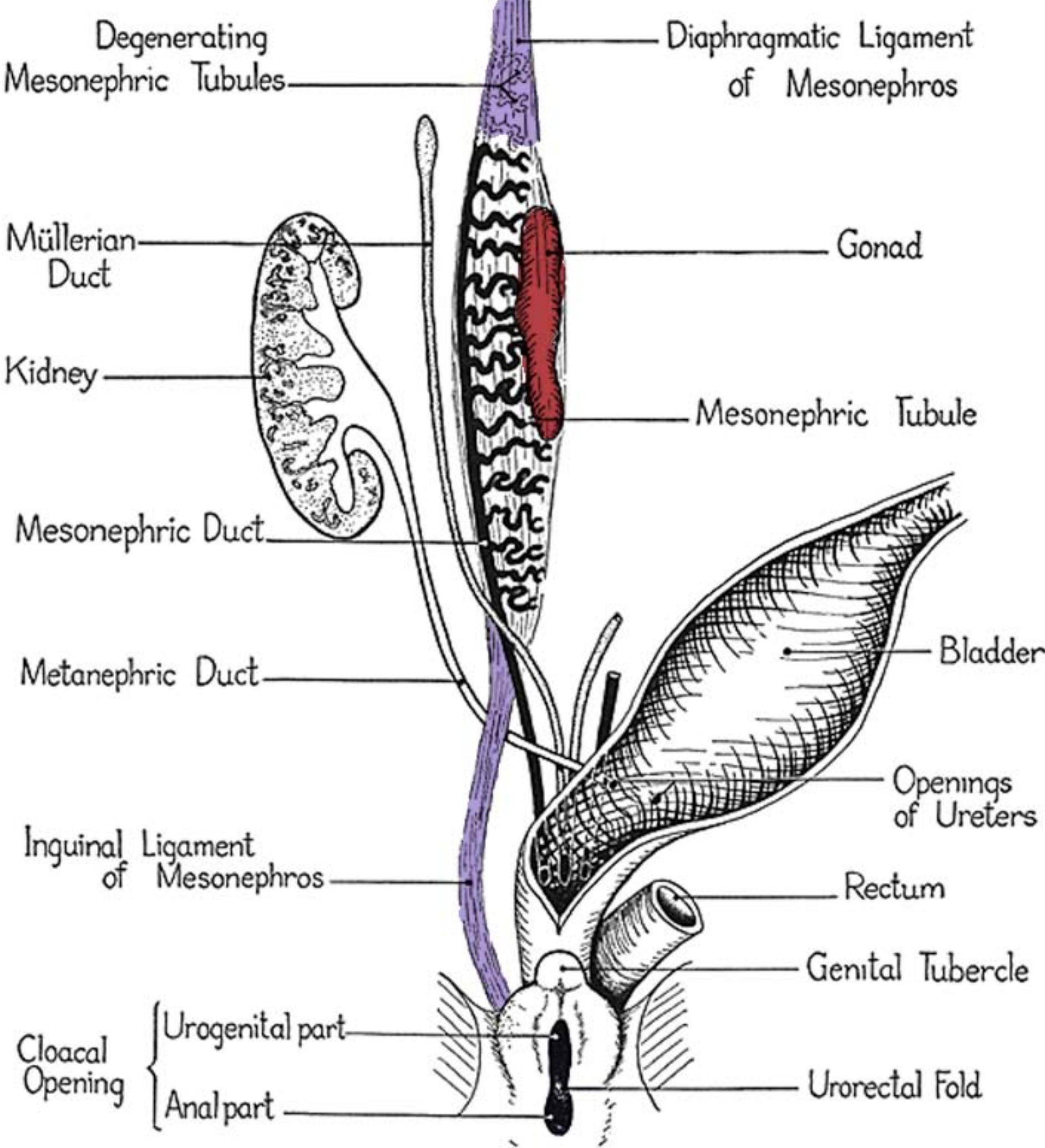
The caudal extension of the genital fold that runs along the body wall and into the inguinal region is called the inguinal fold. It becomes the *proper ligament of the ovary* and *round ligament of the uterus* in females. In males, it gives rise to the *gubernaculum* of the fetus which subsequently in the adult becomes the *proper ligament of the testis* and *ligament of the tail of the epididymis*. These derivatives of the inguinal fold preclude closure of the body wall, and thus are responsible for formation of the inguinal canal and vaginal process (evagination of the coelom).

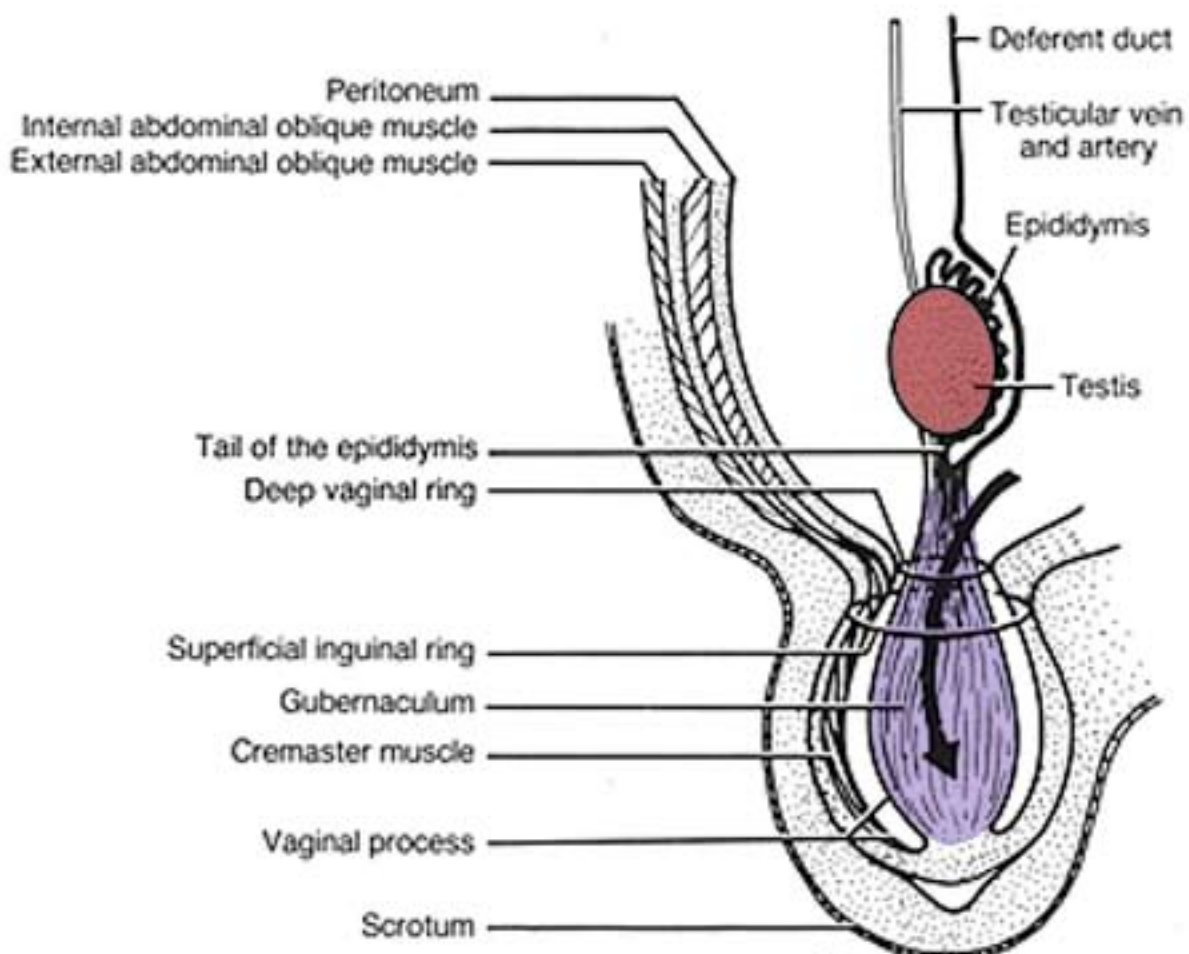
## Descent of the Gonad

In both sexes, there is a caudal shift of the gonad from its original position. The shift is due to elongation of the body and a variable degree of retention by the inguinal fold derivative that indirectly attaches to the gonad. In females, the ovary remains intra-abdominal and the extent of caudal shift is species dependent (e.g., slight in the bitch vs. descent into the pelvis in the cow). In males, each testis descends to the inguinal region (scrotum).

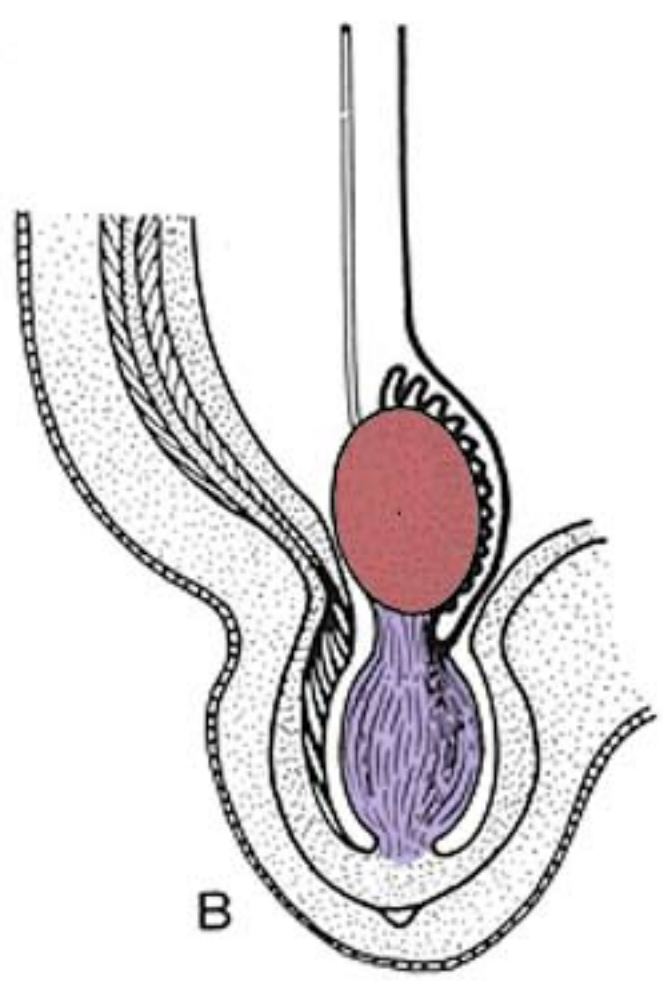
**Testicular descent.** The *gubernaculum* arises from condensation of the mesenchyme within the inguinal fold. Under the influence of gonadotropins and testicular androgens, the gubernaculum accumulates fluid and become a gel mass as large in diameter as a testis. The swollen gubernaculum enlarges the future inguinal canal. Subsequent outgrowth of the scrotal wall and dehydration of the gubernaculum passively pulls the testis to the inguinal canal. Subsequently, a sudden increase in intra-abdominal pressure can pop it through the canal into the scrotum.



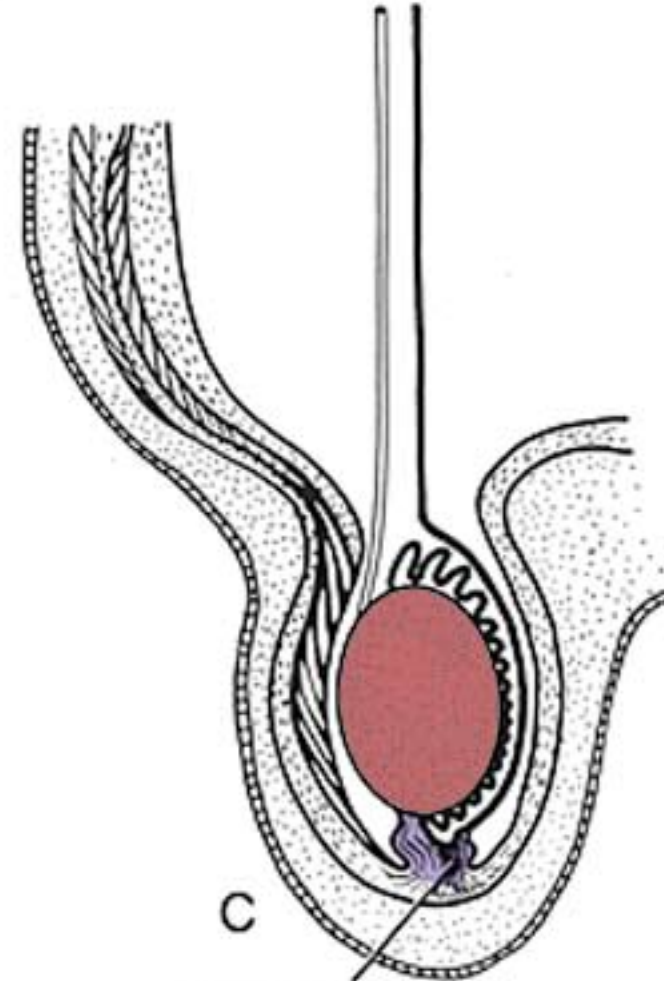




A

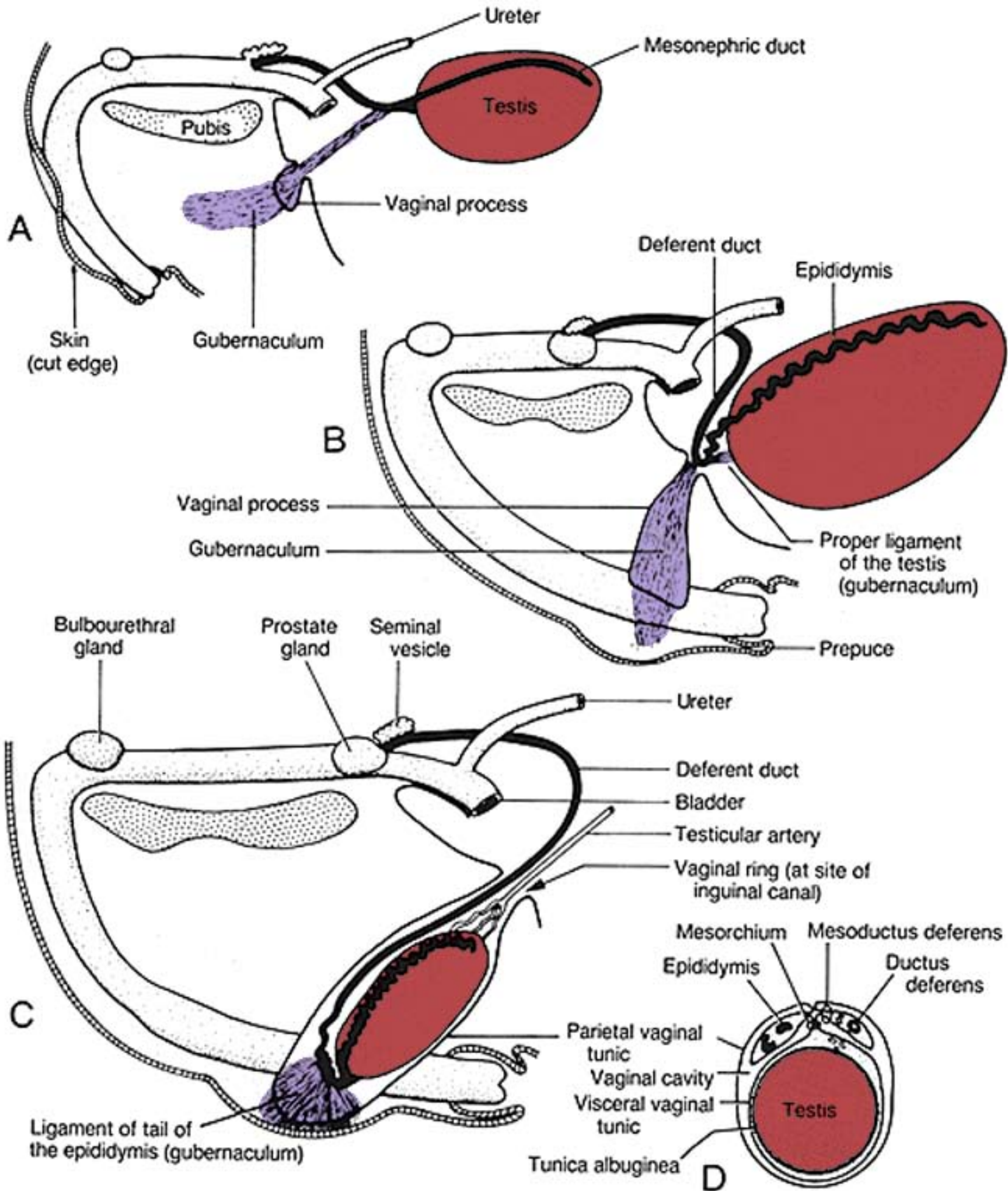


B



C

Ligament of the tail of the epididymis

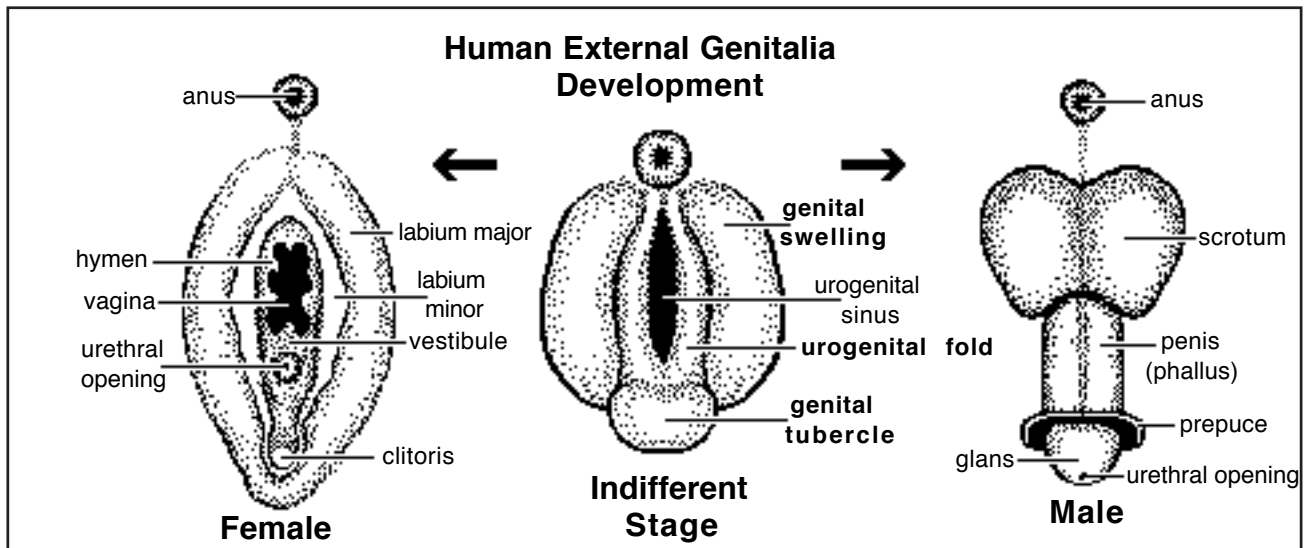


Descent of the testis in the horse, shown in schematic right lateral views

## External Genitalia

**Indifferent stage.** External genitalia are derived from three different swellings (mesoderm proliferations) that appear in the perineal region:

- bilateral *urogenital folds* border the urogenital orifice, the folds and the orifice elongate ventrally (Urogenital folds are formed when the urorectal septum divides the cloaca. Cloacal folds become urogenital folds and anal folds surrounding their respective orifices.)
- a *genital tubercle*, develops at the ventral commissure of the urogenital folds;
- bilateral *genital (labioscrotal) swellings* are located lateral to the urogenital swellings (in domestic mammals these persist only in males, unlike primates where the swellings develop in both sexes, forming major labia in females and scrotum in males).



**Female.** The urogenital orifice becomes the *vulval cleft*, which opens into the vestibule (urogenital sinus). The genital tubercle becomes the *clitoris*. The urogenital folds enlarge, overgrow the genital tubercle, and become *labia* of the vulva. Genital swellings disappear in female domestic mammals (but they become major labia in primates).

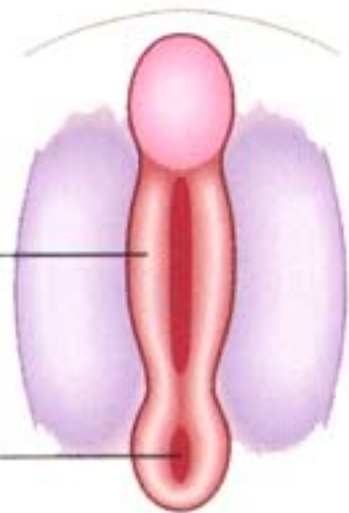
**Male.** Growth at the base of the genital tubercle generates an elongate phallus. The original genital tubercle becomes *glans* at the tip of the phallus. The urogenital orifice (sinus) elongates along with the phallus forming a urogenital groove. The *penile urethra* is created when the groove closes by medial merger of urogenital folds in proximal to distal sequence.

The opening of the distal end of the penile urethra, within the original genital tubercle, is created by ectoderm invasion and canalization which establishes communication between the exterior and the endodermal penile urethra. Genital tubercle mesenchyme gives rise to penile erectile tissue, tunica albuginea, muscle, and bone (carnivores).

The *prepuce* is formed when a ring of ectoderm that invades into the mesenchyme of the free end of the phallus, dividing tissue into a penis encircled by preputial skin. (Except in the cat, the phallus of domestic mammals elongates deep to the skin of the ventral body wall.)

Genital swellings enlarge and merge at the midline to form a single scrotum (with two compartments). The scrotum initially overlies the gubernaculum and vaginal process caudally in the inguinal region, and then it generally shifts cranially (except that it remains caudal in the cat and pig).

**Female**



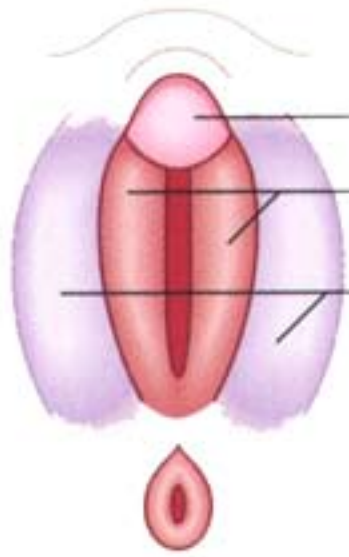
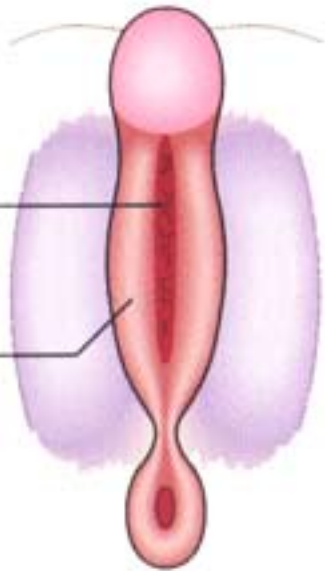
Urogenital fold

Anal membrane

**The indifferent stage**

Urogenital membrane breaks down

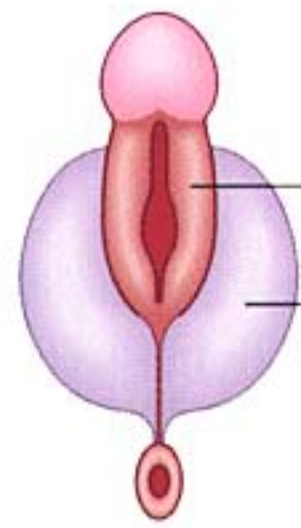
Urethral fold



Clitoris

Labia minora

Labia majora



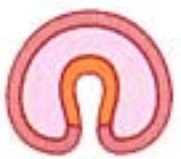Urethral fold

Scrotal swelling

**Male**

Phallus

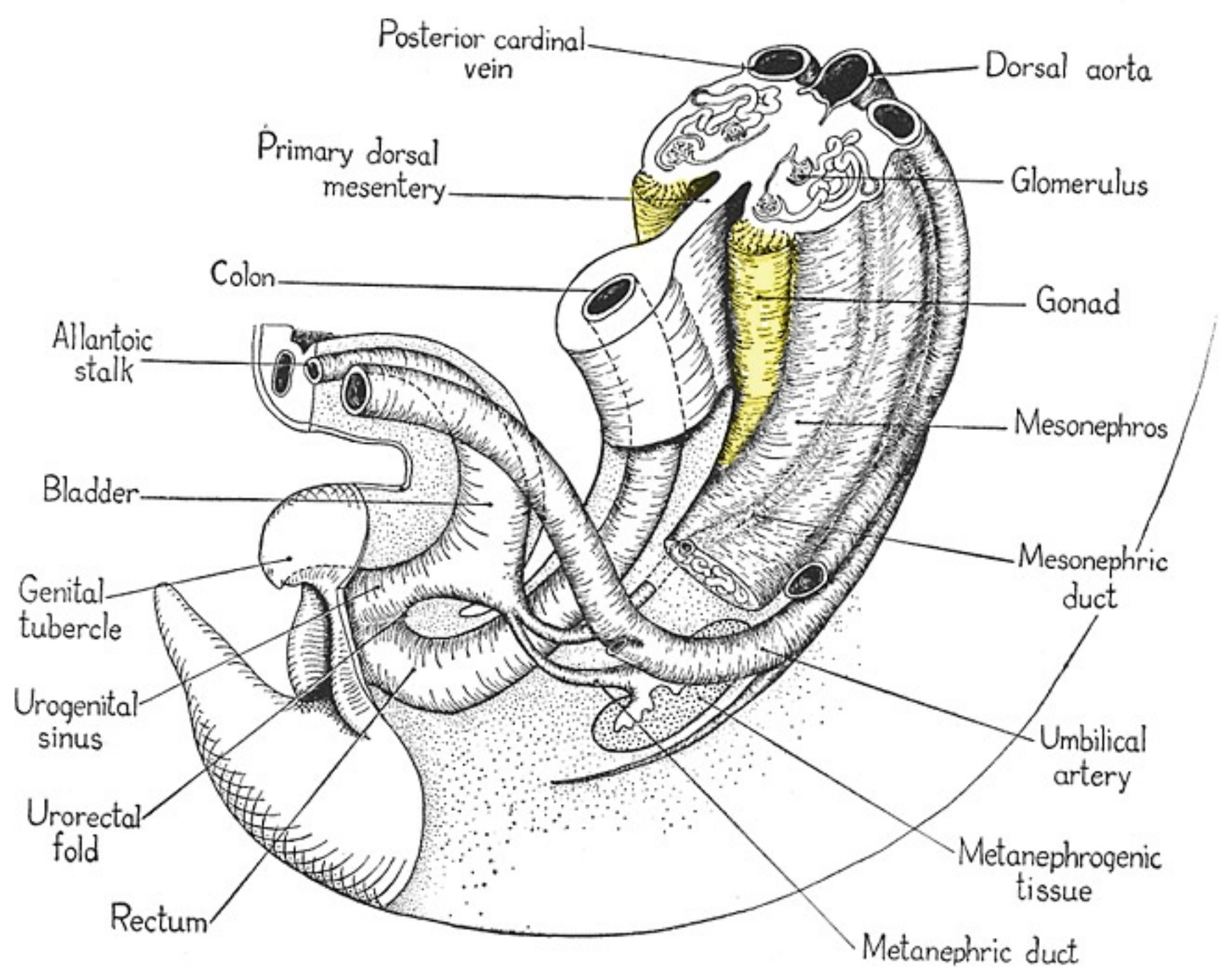
**Formation of penile urethra**

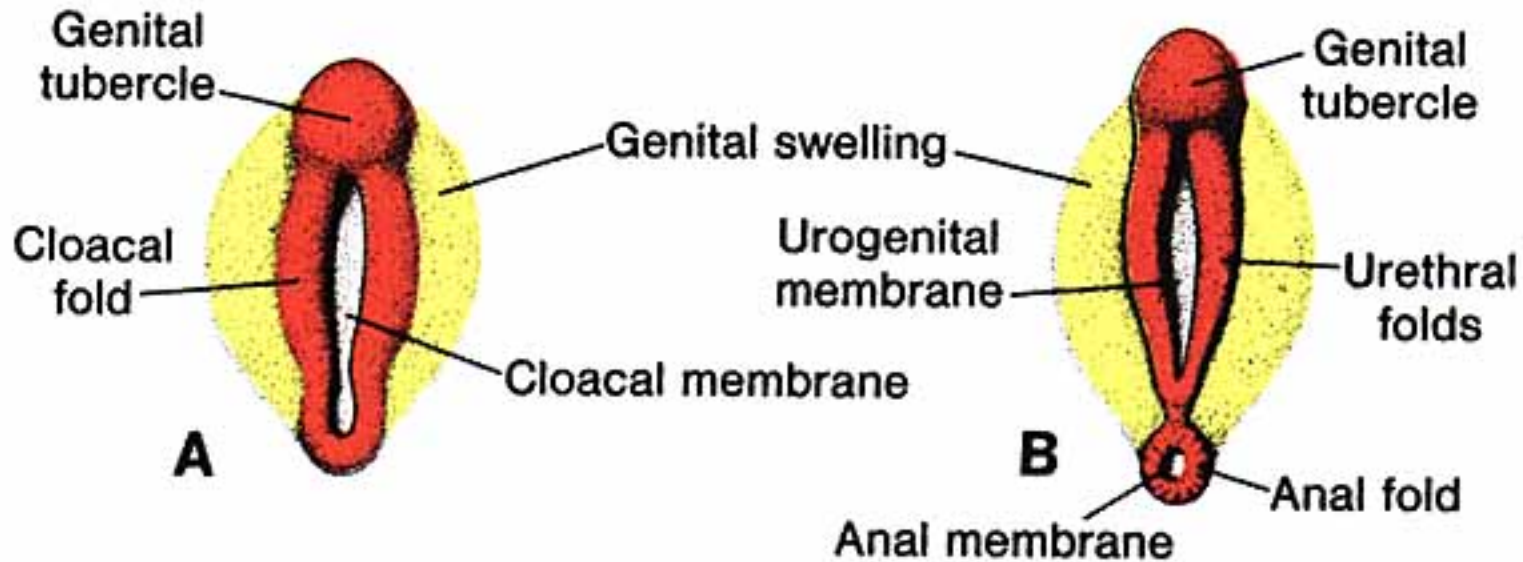


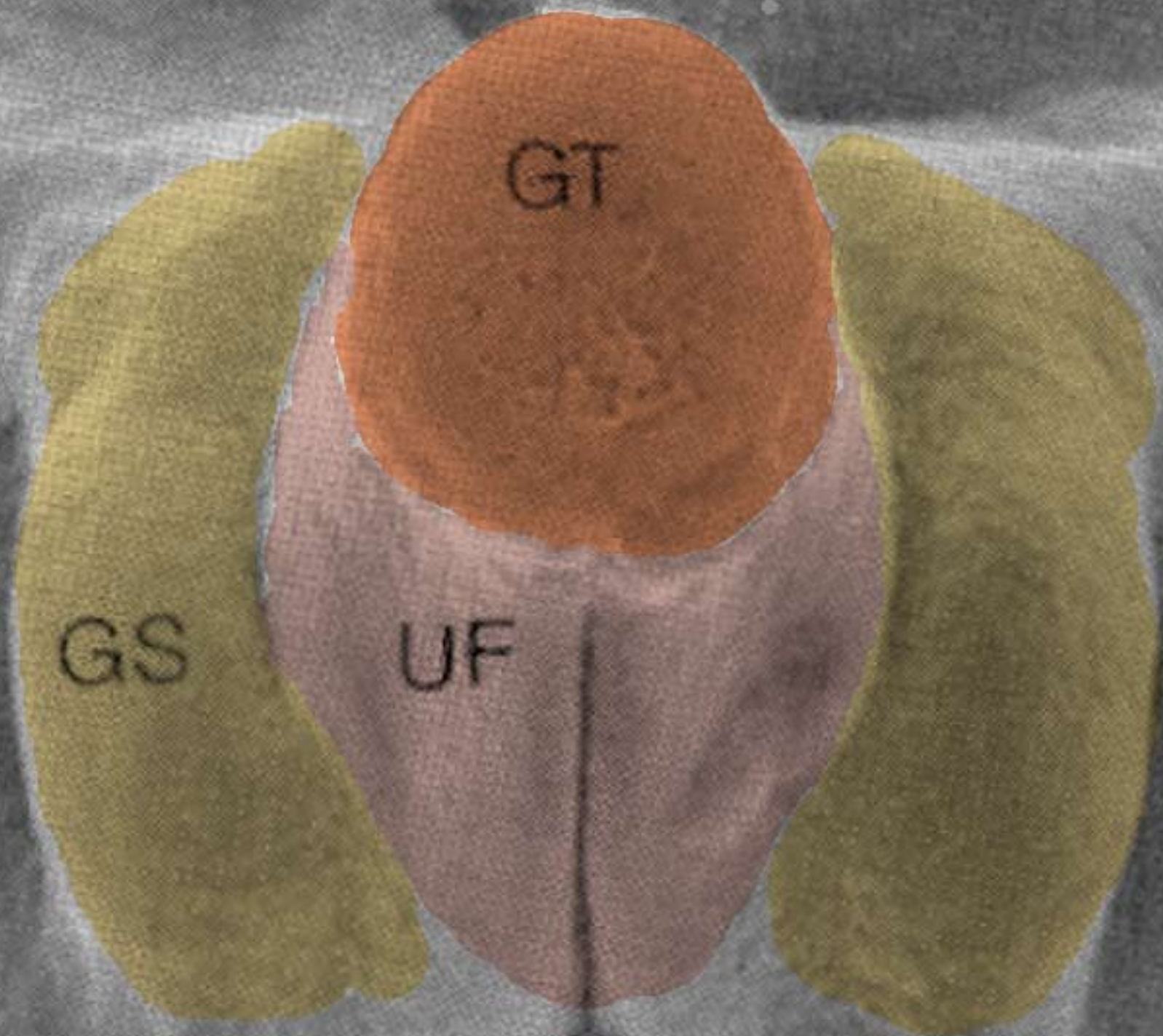
Late 7 wk



Line of fusion





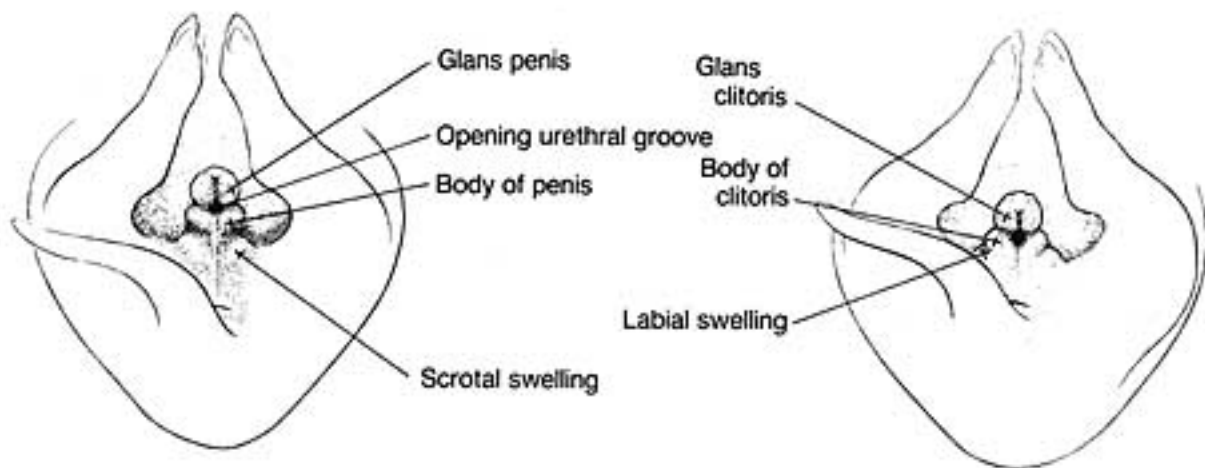
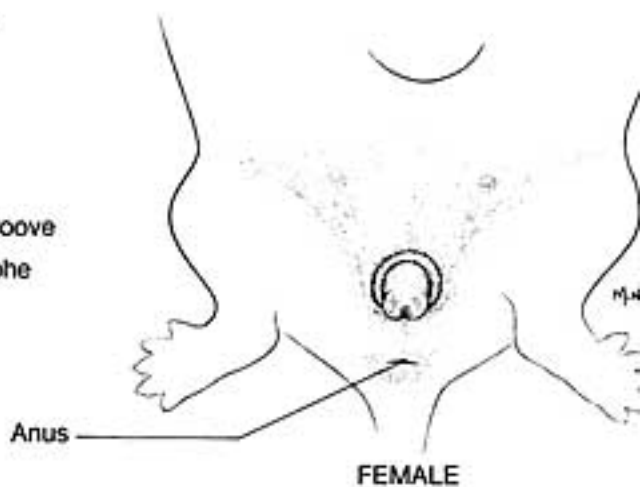
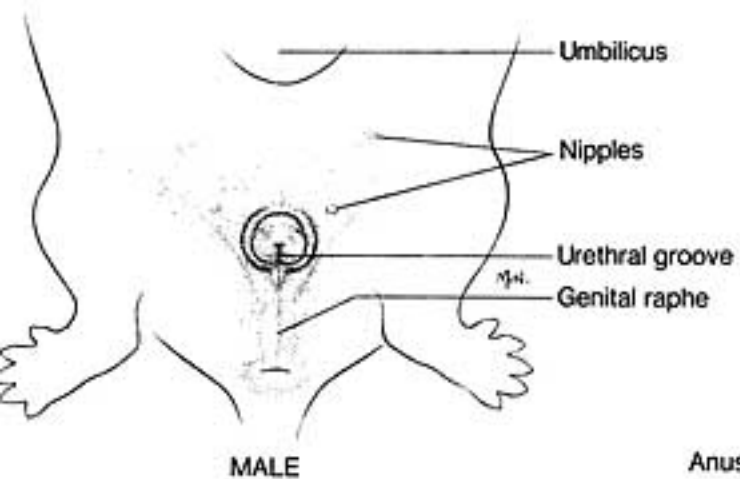
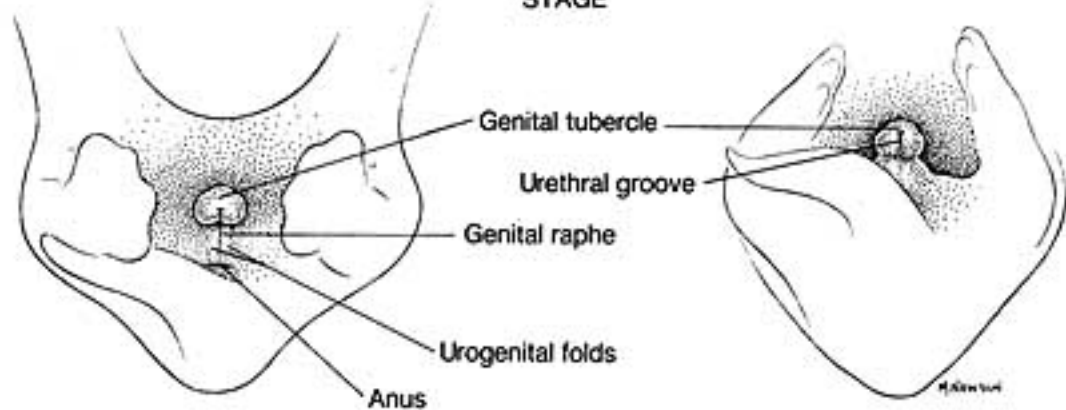


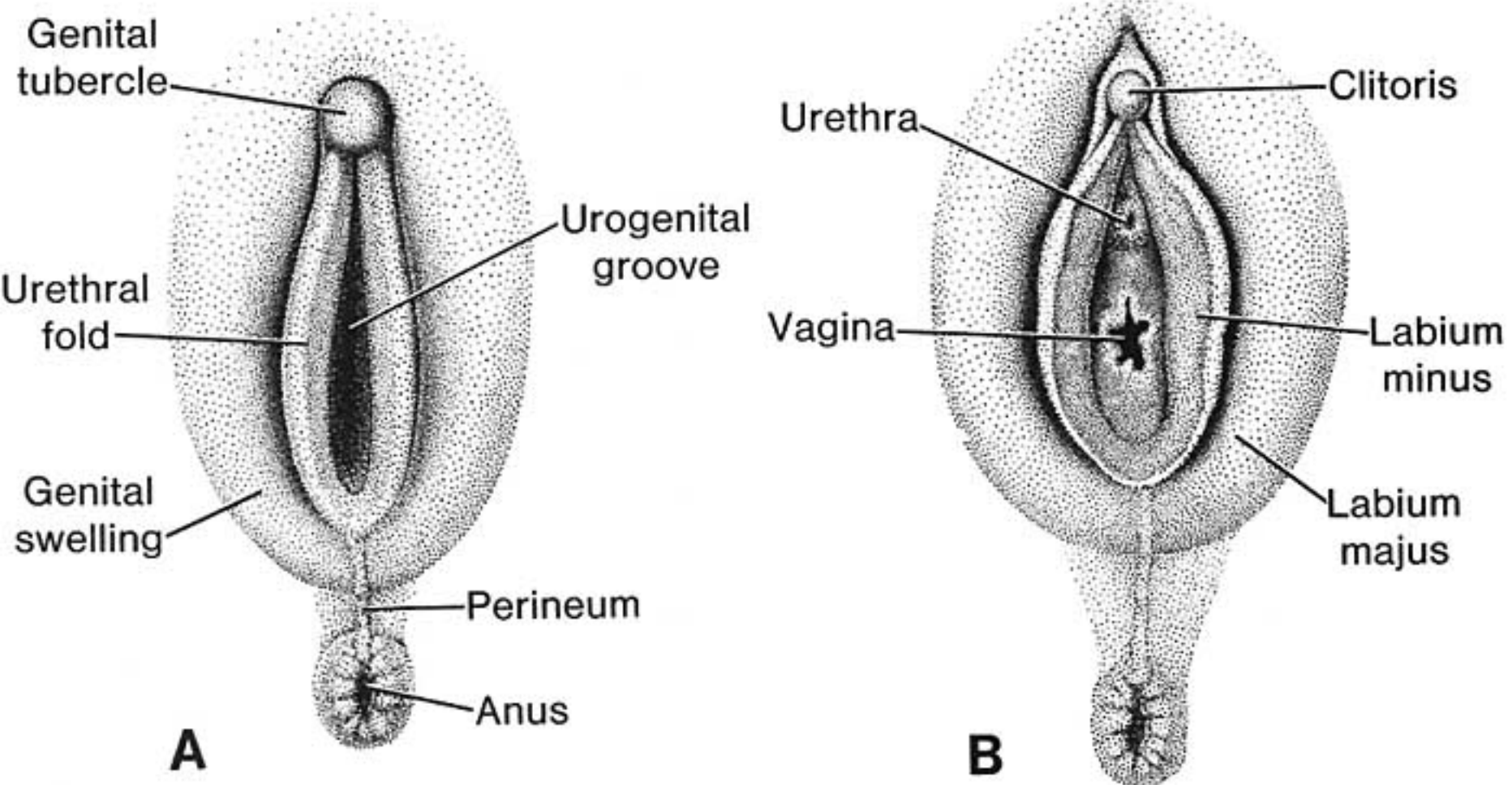
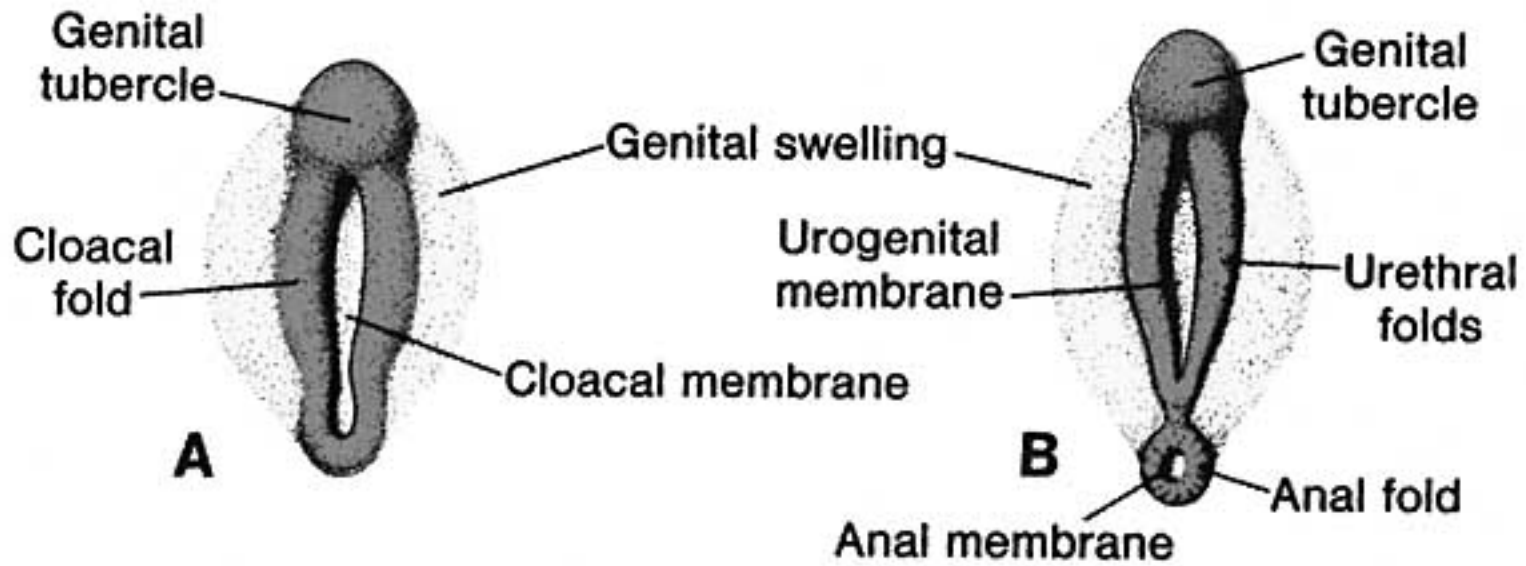
AF

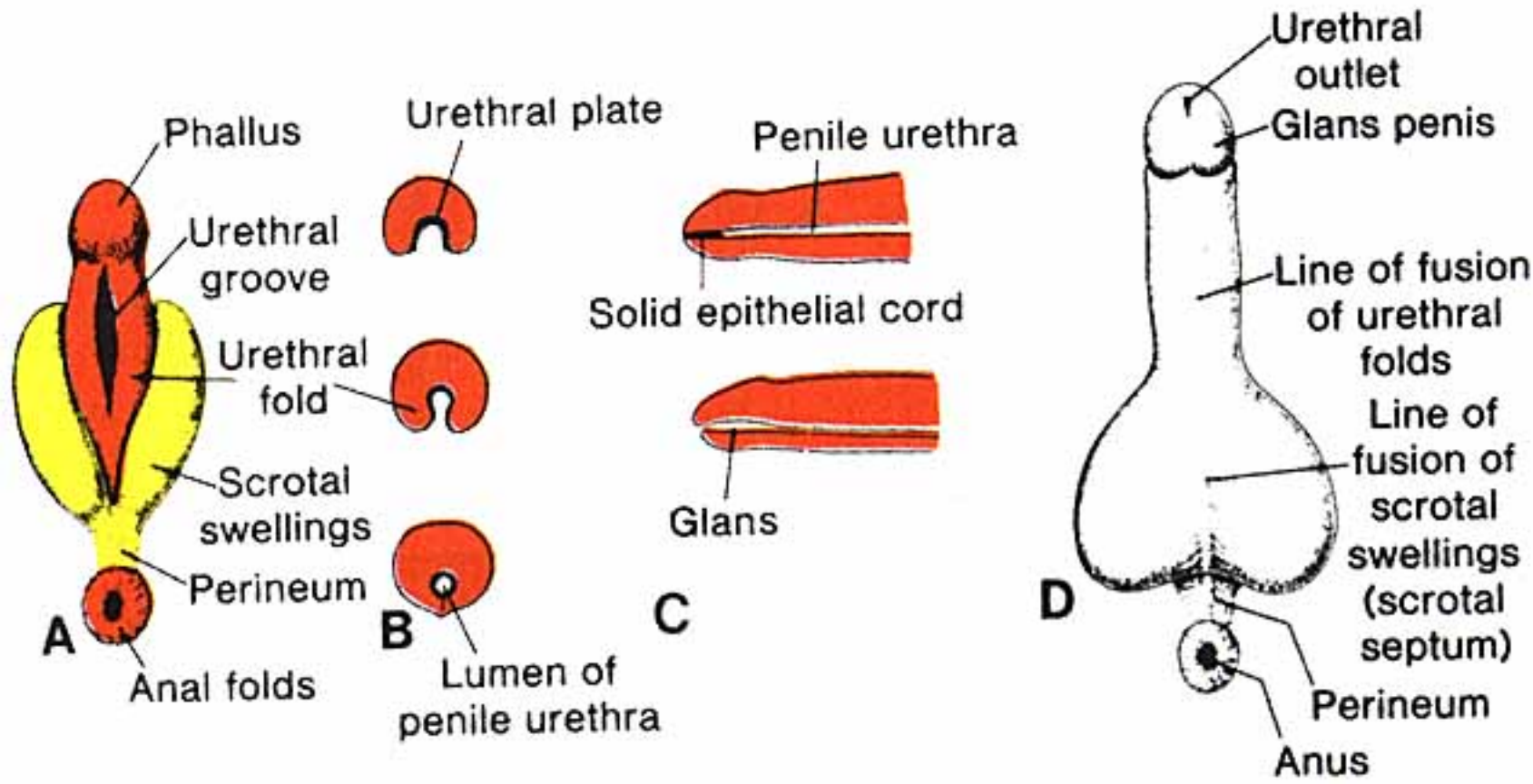
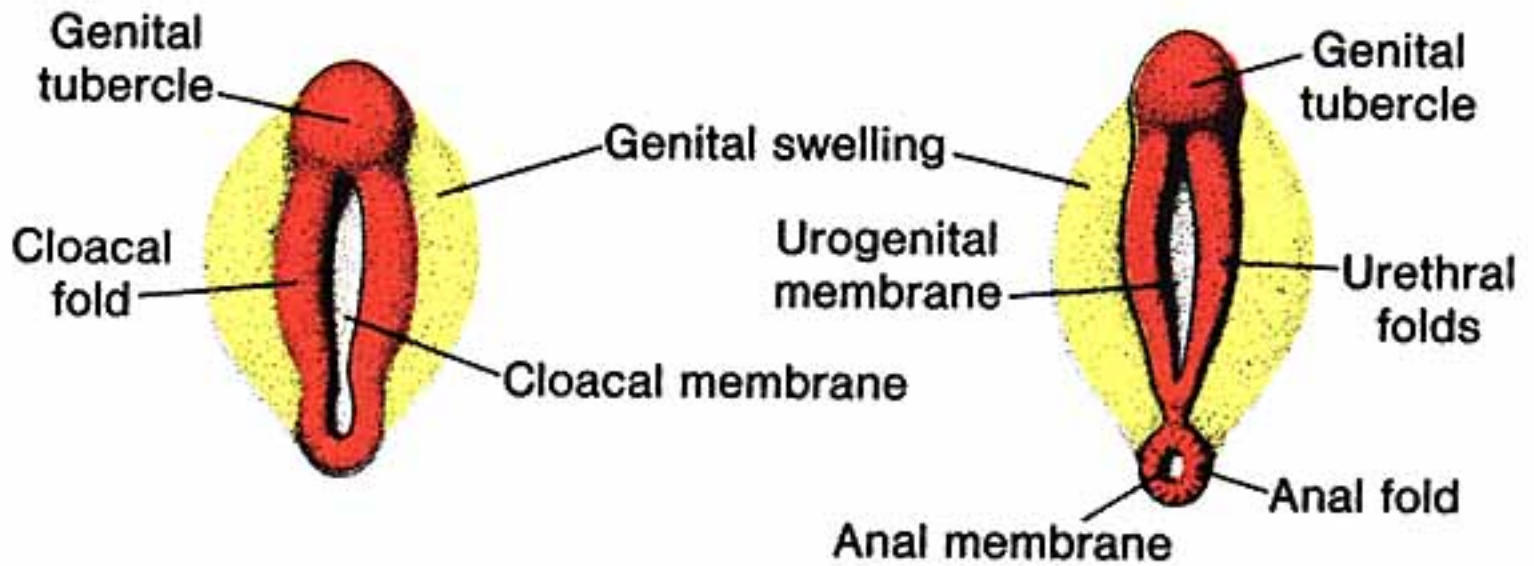
AF

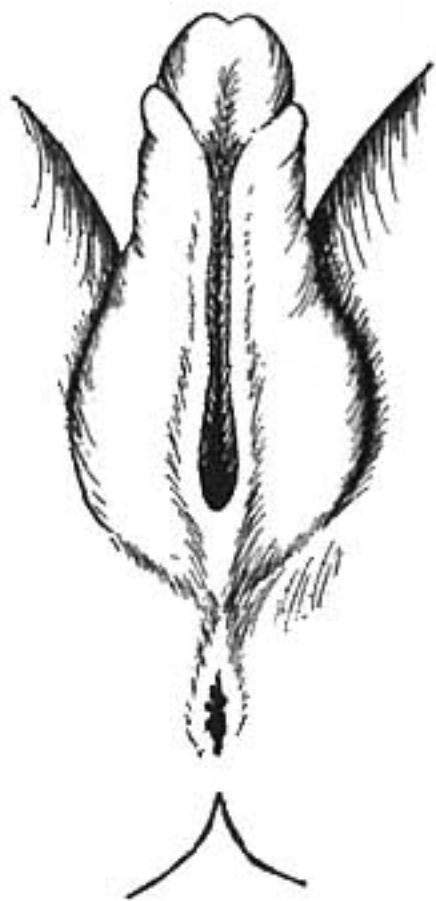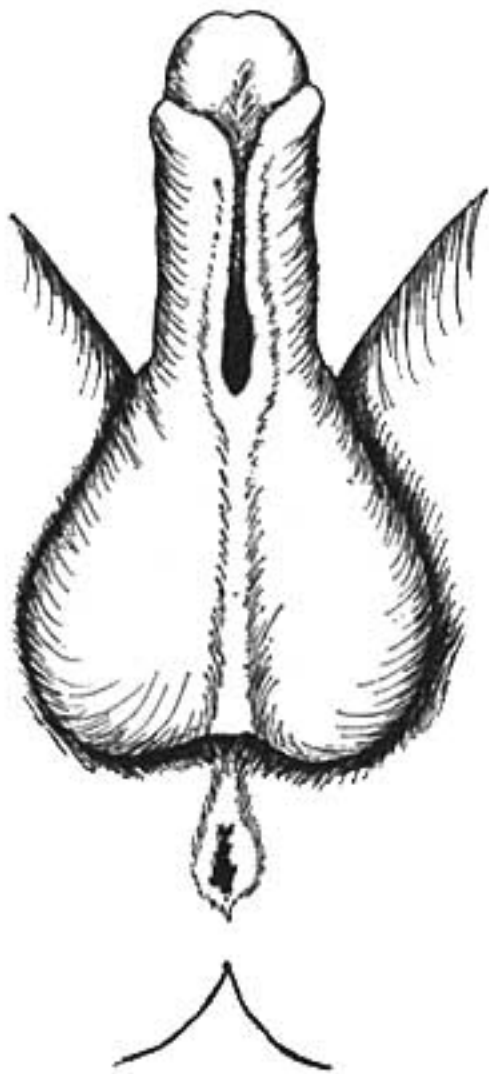
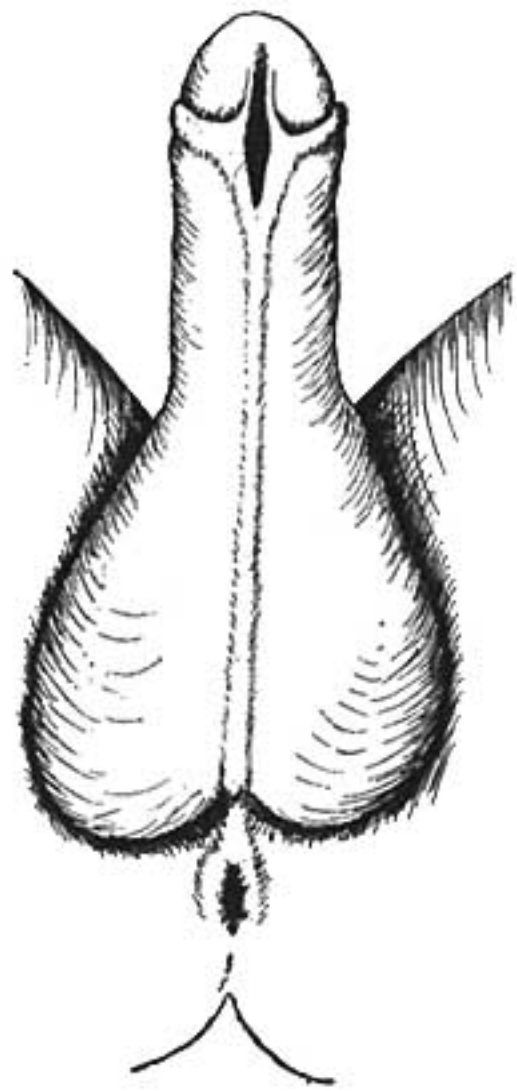
This diagram illustrates a cross-section of a flower. At the bottom is a small, white, pointed structure labeled 'AF', representing the apical meristem or the base of the flower. The entire flower is shown in a cross-section, revealing its internal structure.

INDIFFERENT  
STAGE









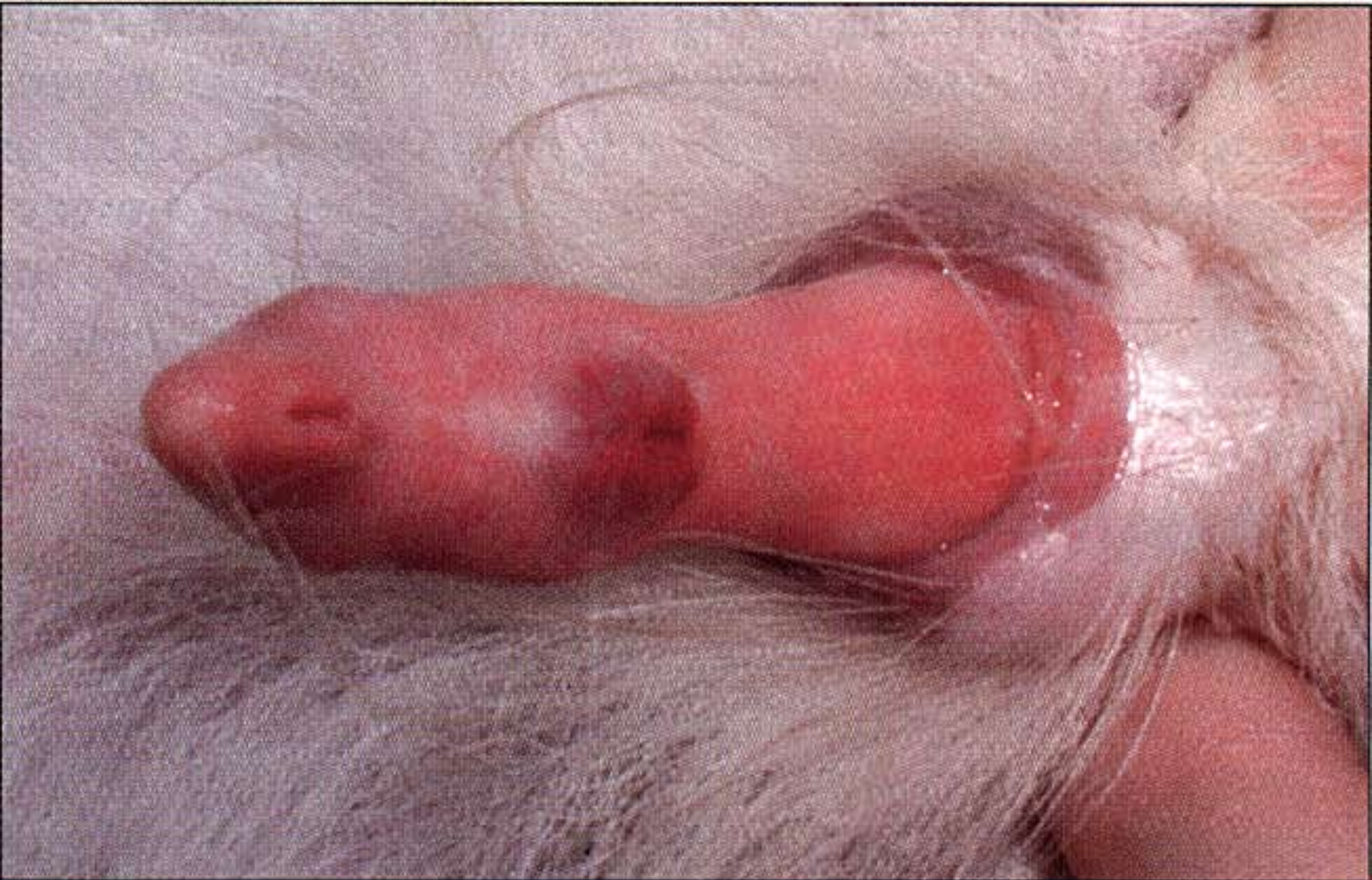


Figure 1—Photograph of the ventral surface of the penis of a 4.5-year-old Papillon.

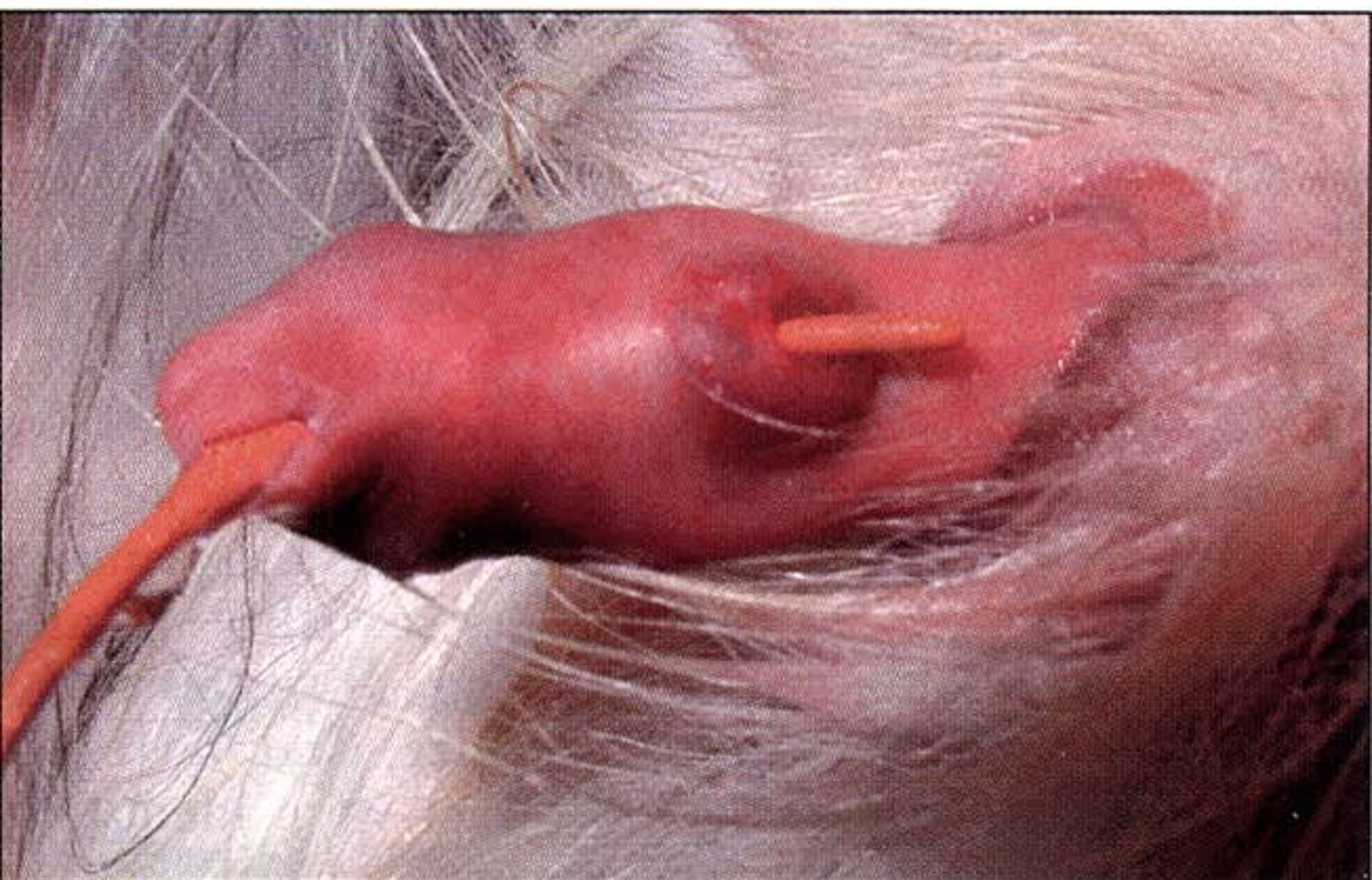

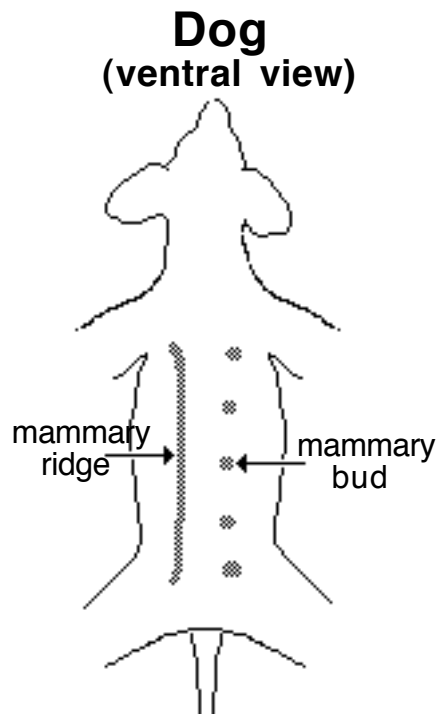
Figure 2—Photograph of the ventral surface of the penis of the dog in Figure 1 after insertion of a catheter.

## Mammary Glands

In both sexes, a mammary ridge (line) of thickened ectoderm forms bilaterally from the axillary to the inguinal region. *Mammary buds* develop periodically along the ridge; elsewhere, mammary ridge ectoderm regresses. Buds determine the number and locations of mammary glands, since each bud develops into a *mammary gland* (2, sheep, goat, mare; 4 cow; 8, queen; 10, bitch; 14; sow).

At each mammary bud, ectoderm induces proliferation of underlying mesoderm (teat formation) and mesoderm induces epithelial cell proliferation. Epithelial cell cords invade underlying mesoderm and eventually canalize to form epithelial lined lactiferous ducts. The number of cell cord invasions and subsequent lactiferous duct systems per teat is species dependent (approximately: 1, sheep, goat, cow ; 2 mare sow; 6, queen; 12, bitch). In some cases, multiple lactiferous ducts open into a pit (inverted nipple) that becomes a nipple following proliferation of underlying mesoderm.

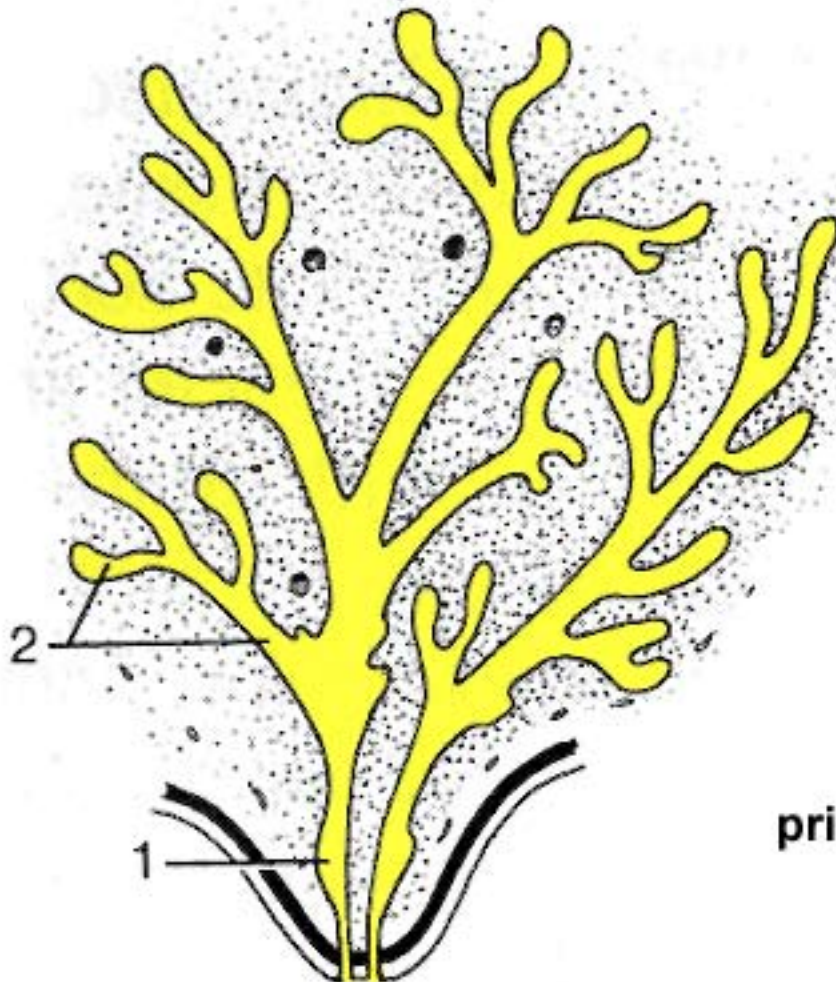
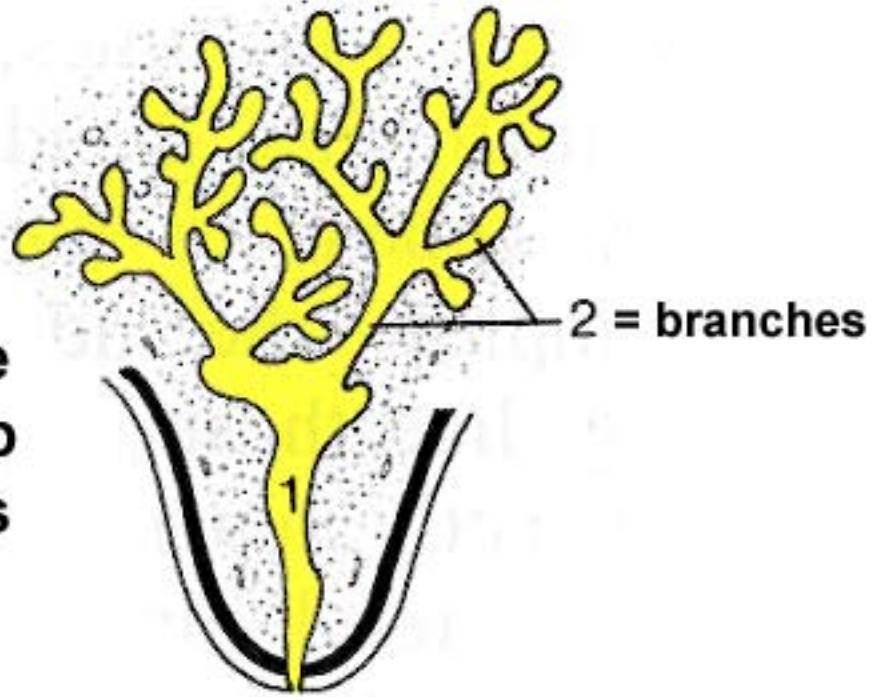
Commonly, extra buds develop and degenerate, failure to degenerate results in supernumerary teats.



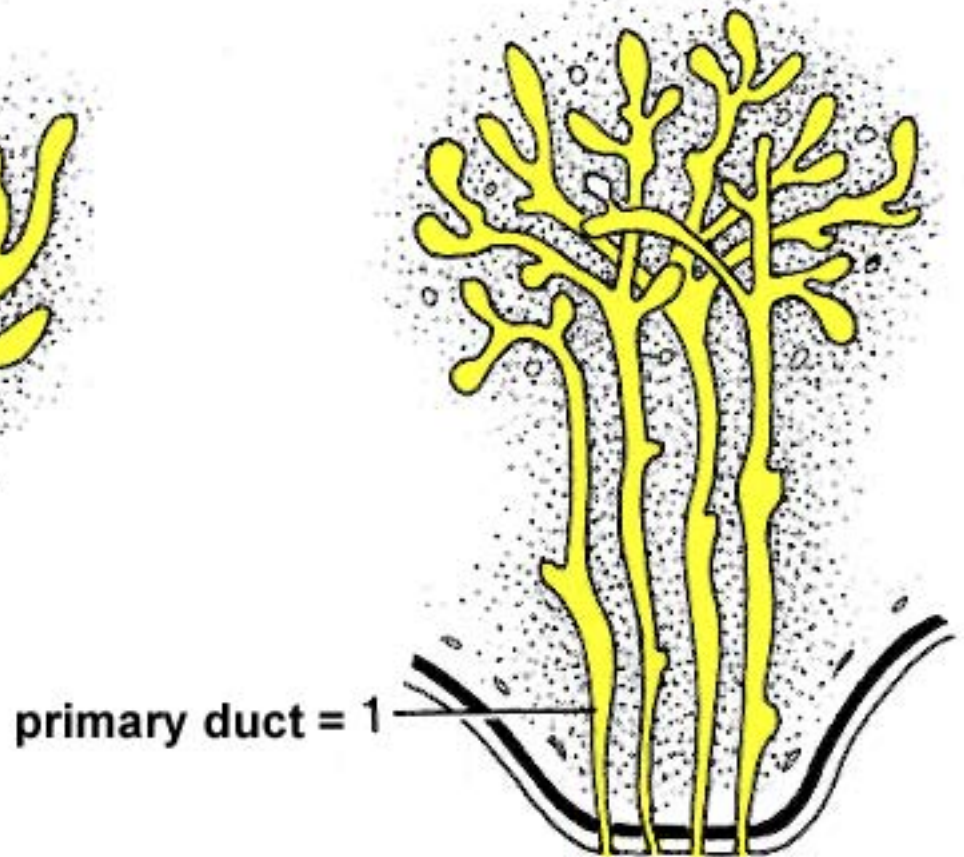
# Latiferous Ducts Per Teat Per Species

Dyce, TVA p.363

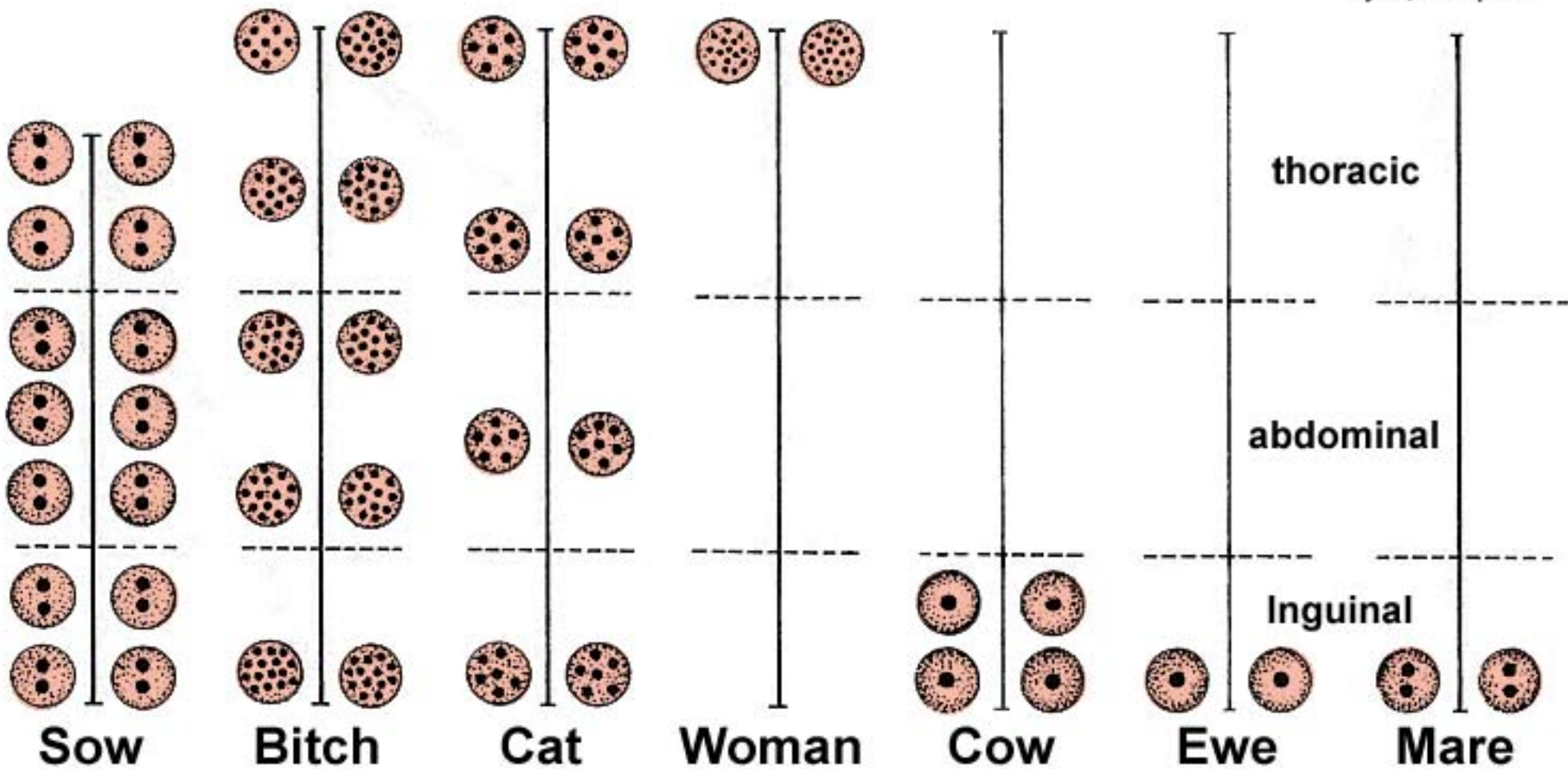
Cattle  
Sheep  
Goats



Mare & Sow



Carnivore



# Duct Openings Per Teat Per Species

# What's a Monotreme?

**A monotreme is a rare sort of mammal found in Australia, Tasmania and New Guinea. The reason they are so rare is that they lay eggs!**

**This group includes the Platypus and the Echidna (spiny anteater).**

**The platypus is a semi-aquatic creature with webbed feet, a bill (sort of like a duck), waterproof fur and a flat tail (like a beaver). They are between 1 and 2 feet long and between 3 or 4 pounds. Some of their bones are a lot like a reptile's and it lays eggs like a reptile. But it's still considered a mammal. It eats insect larvae, shrimp, frogs and fish eggs.**

**Echidna's have spines and VERY long, sticky tongues that they use to catch termites and ants. Echidna's are also between 1 and 2 feet long.**

