Cochlea and Auditory Pathways

Anatomical Considerations

External ear:

The external auditory meatus (canal) is formed by auricular and annular cartilages, plus a short contribution from the temporal bone.

Middle ear:

Air-filled tympanic cavity (including a ventrally expanded bulla) that features:

— four openings (three sealed by membranes):

- auditory tube opening (not sealed) connects middle ear to the nasopharynx;
- tympanic membrane (ear drum) separates tympanic cavity from external auditory meatus;
- oval (vestibular) window separates the tympanic cavity from perilymph in the vestibule;
- round (cochlear) window separates tympanic cavity from perilymph in the scala tympani;

— three ossicles, *malleus, incus,* and *stapes,* transmit tympanic membrane movements to the membrane of the oval window;

— two muscles reflexly dampen ossicle movement, to suppress forceful low frequencies:

- *stapedius muscle*, innervated by facial nerve, pulls the stapes away from oval window;
- *tensor tympani muscle*, innervated by trigeminal nerve, pulls malleus thus tensing the tympanic membrane.

Function of Middle Ear

To increases the efficiency of sound transmission. (Pressure oscillations in air (sound waves) are very inefficiently converted to pressure waves in fluid, only 0.1% of the force is normally transmitted.) Middle ear components convert large amplitude, low force input into low amplitude, high force output. (The middle ear matches low impedance input to high impedance output.)

Note: The tympanic membrane occupies a large area and undergoes a large excursion, offering low resistance to being vibrated (by air pressure waves). The membrane of the oval window has a small area and makes small excursions against high resistance load (it must push against incompressible perilymph fluid and the round window. The ossicles form a lever system that collects energy from the large tympanic membrane and focuses it on the small oval window membrane (yielding a 60-fold force gain in the cat).

Inner ear:

The inner ear consists of the **cochlea** and vestibular apparatus. The cochlea is a component of osseous labyrinth that contains perilymph and the cochlear duct. The cochlear duct is a component of membranous labyrinth and contains endolymph.

The cochlea makes 3.25 turns in the dog (2.5 in man) around a core of bone (called the modiolus) through which the cochlear nerve passes. The entire complex resembles a snail's shell (whence the term cochlea is derived).

Within the cochlea, the **cochlea duct** (scala media) separates two perilymph chambers: the **scala vestibuli**, which contacts the oval window membrane, and the **scala tympani**, which contacts the round window membrane.

Perilymph can flow from one scala to the other through an opening (helicotrema) at the apex of the cochlea. The helicotrema is non-functional with respect to the physiology of hearing, it merely precludes perilymph stagnation.

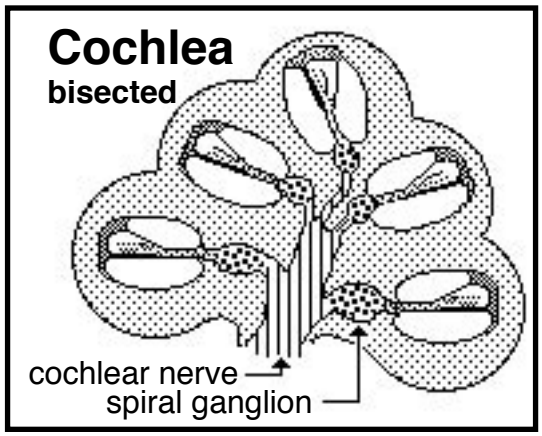

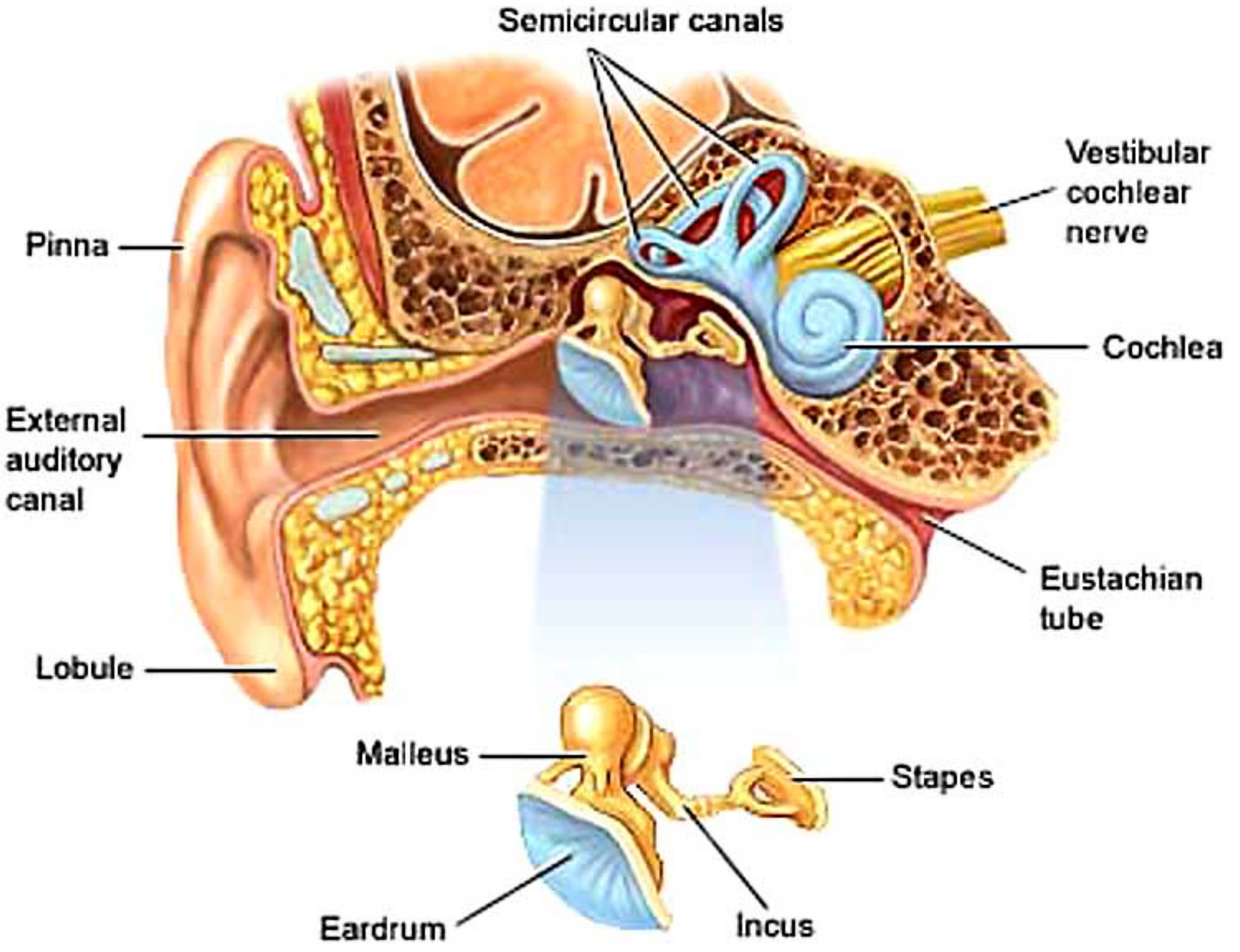
Semicircular canals
Vestibular cochlear nerve
Pinna
Cochlea
External auditory canal
Eustachian tube
Lobule
Malleus
Stapes
Eardrum
Incus
A.D.A.M.

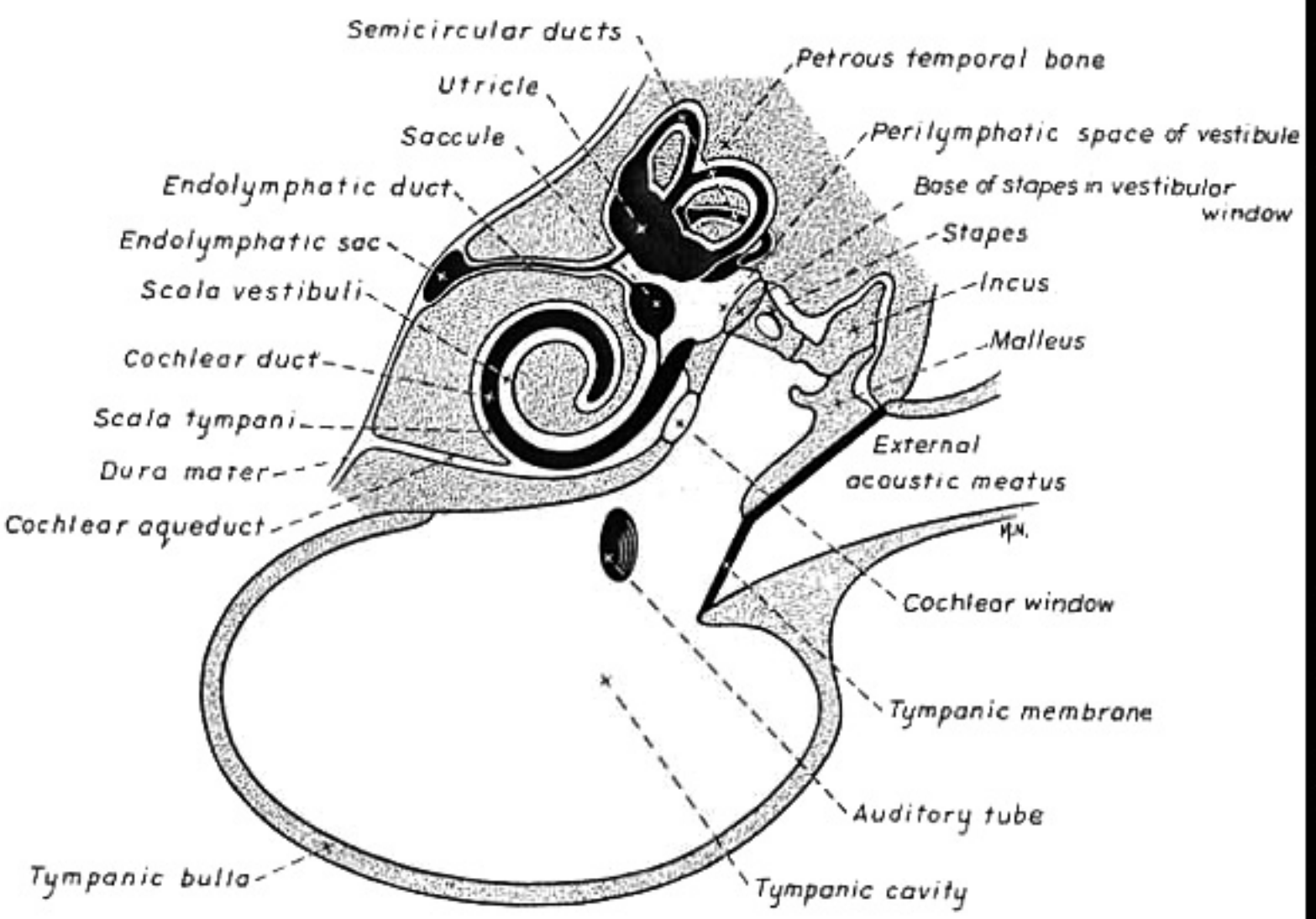
Semicircular ducts
Petrous temporal bone
Utricle
Saccule
Perilymphatic space of vestibule
Endolymphatic duct
Base of stapes in vestibular window
Endolymphatic sac
Stapes
Scala vestibuli
Incus
Malleus
Cochlear duct
Scala tympani
External acoustic meatus
Dura mater
Cochlear aqueduct
M.N.
Cochlear window
Tympanic membrane
Auditory tube
Tympanic bulla
Tympanic cavity

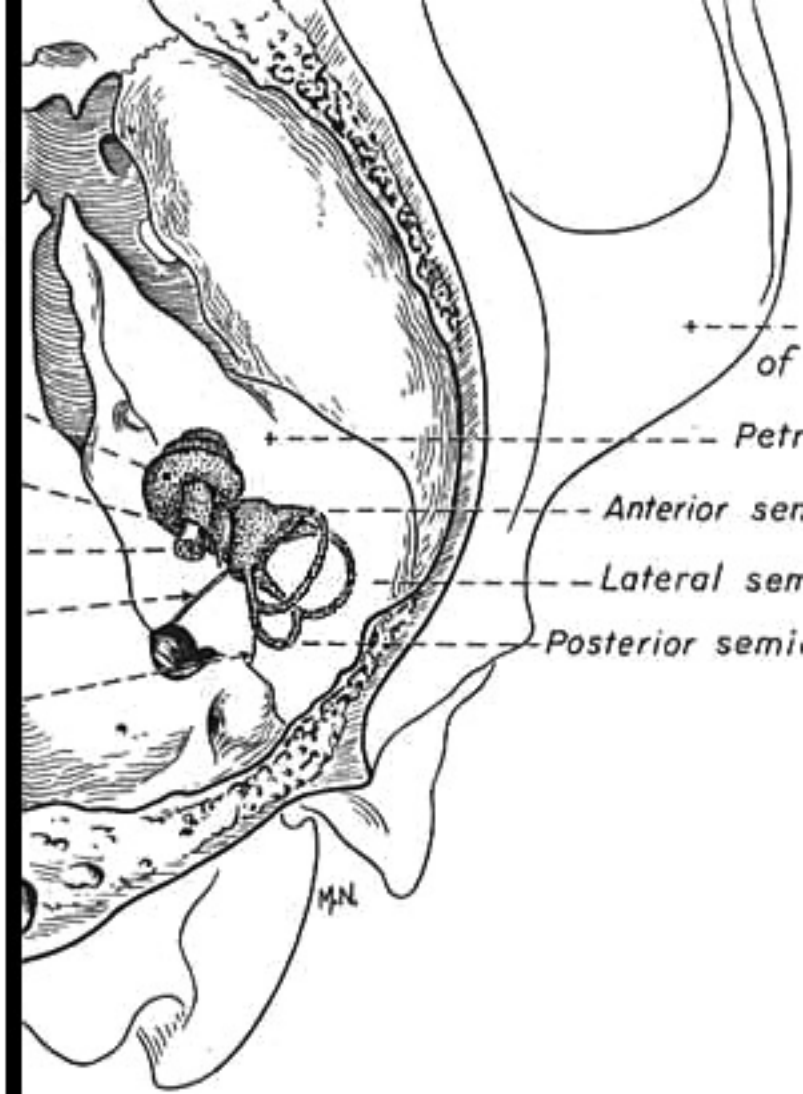
of
Petr
Anterior sem
Lateral sem
Posterior semi
M.N.

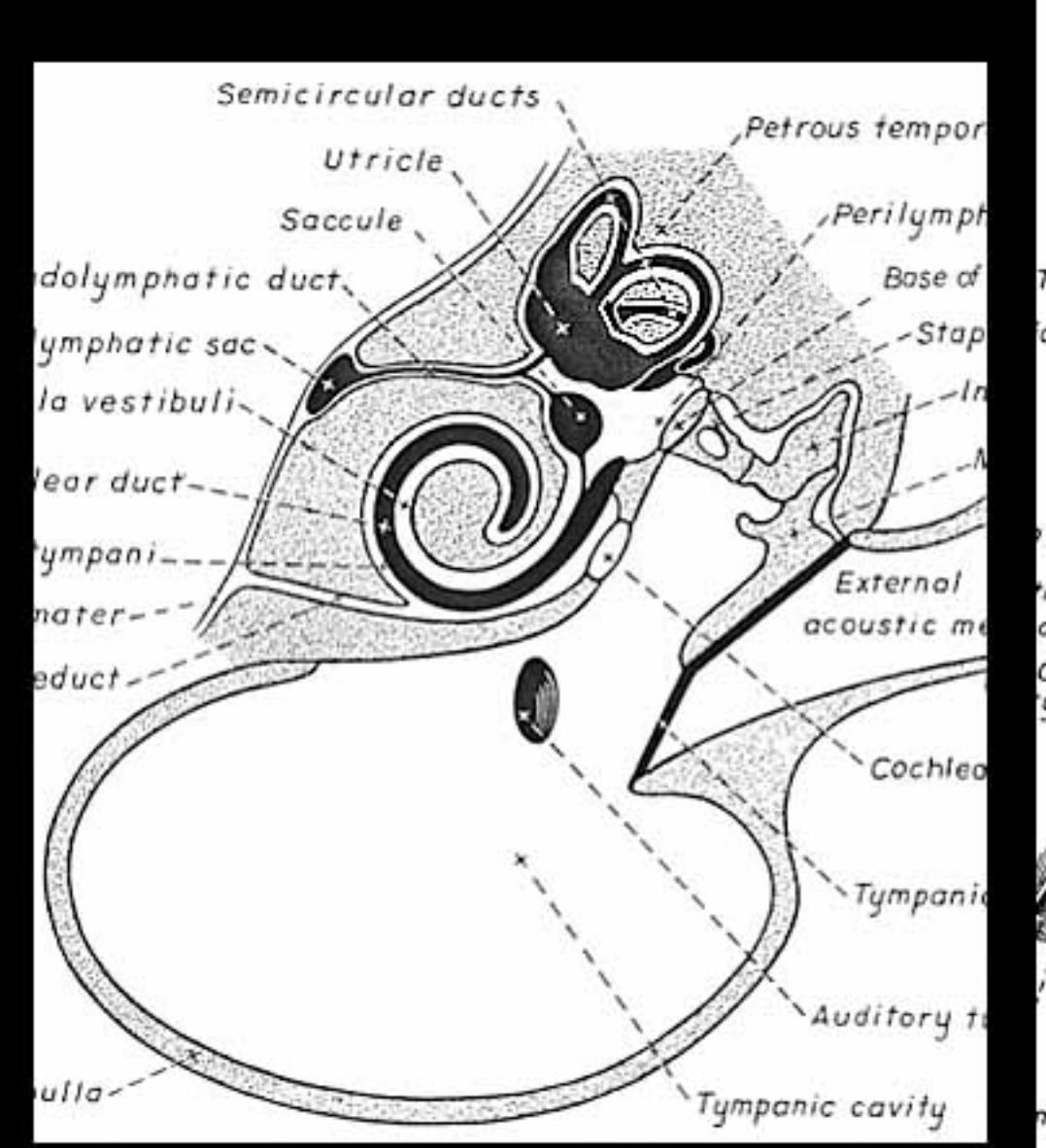
Semicircular ducts
Petrous tempor
Utricle
Saccule
Perilympt
dolymphatic duct
Base of
ymphatic sac
Stap
la vestibuli
In
ear duct
ympani
External
nater
acoustic me
educt
Cochlea
Tympanic
Auditory t
ulla
Tympanic cavity

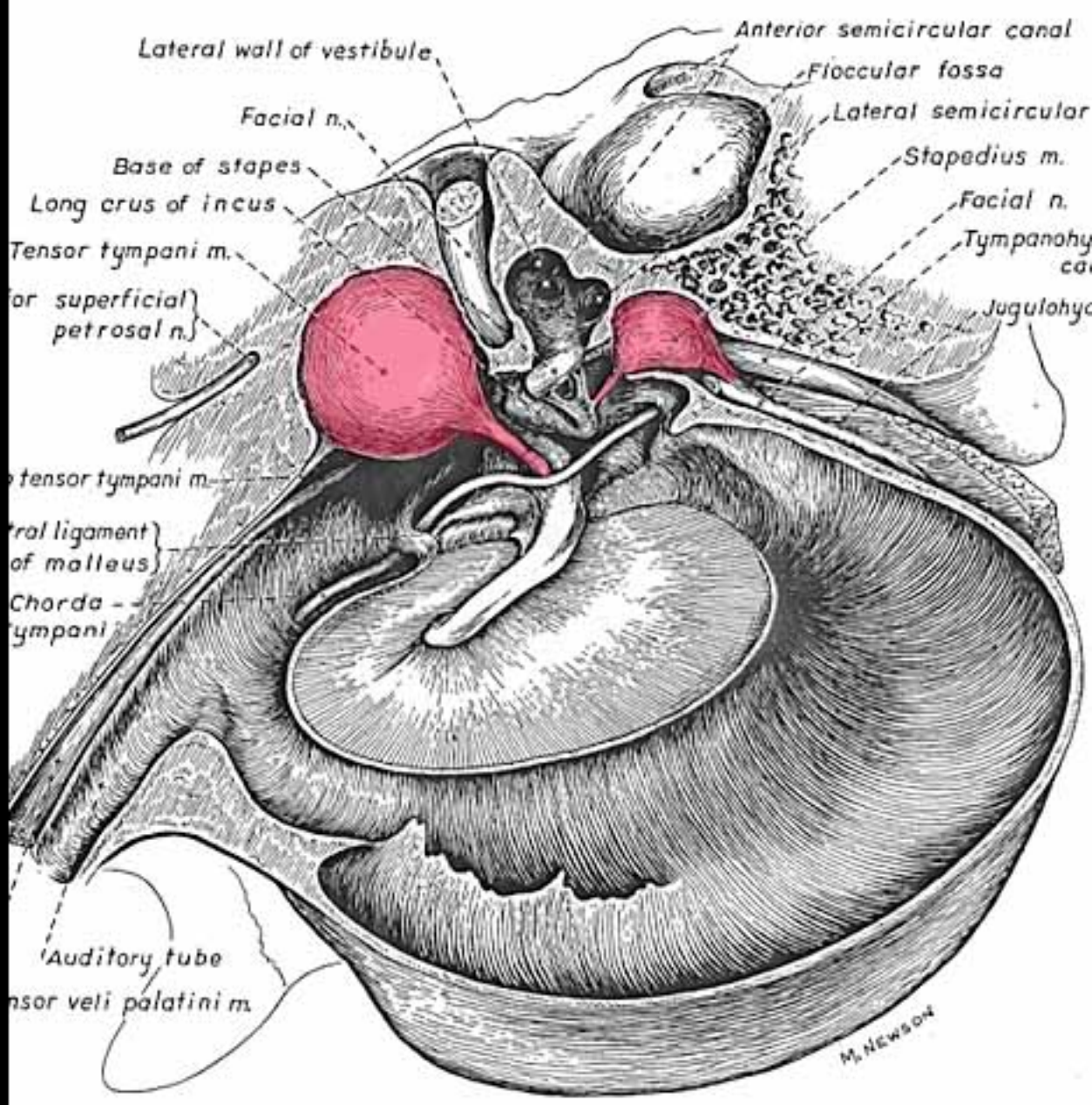
Anterior semicircular canal
Lateral wall of vestibule
Flocculer fossa
Facial n.
Lateral semicircular
Base of stapes
Stapedius m.
Long crus of incus
Facial n.
Tensor tympani m.
Tympanohy
ca
or superficial
petrosal n.
Jugulohyo
tensor tympani m.
ral ligament
of malleus
Chorda
ympani
Auditory tube
nsor veli palatini m.
M. Newson

Cochlea and Auditory Pathways

Anatomical Considerations

External ear:

The external auditory meatus (canal) is formed by auricular and annular cartilages, plus a short contribution from the temporal bone.

Middle ear:

Air-filled tympanic cavity (including a ventrally expanded bulla) that features:

— four openings (three sealed by membranes):

- auditory tube opening (not sealed) connects middle ear to the nasopharynx;
- tympanic membrane (ear drum) separates tympanic cavity from external auditory meatus;
- oval (vestibular) window separates the tympanic cavity from perilymph in the vestibule;
- round (cochlear) window separates tympanic cavity from perilymph in the scala tympani;

— three ossicles, *malleus, incus,* and *stapes,* transmit tympanic membrane movements to the membrane of the oval window;

— two muscles reflexly dampen ossicle movement, to suppress forceful low frequencies:

- *stapedius muscle*, innervated by facial nerve, pulls the stapes away from oval window;
- *tensor tympani muscle*, innervated by trigeminal nerve, pulls malleus thus tensing the tympanic membrane.

Function of Middle Ear

To increases the efficiency of sound transmission. (Pressure oscillations in air (sound waves) are very inefficiently converted to pressure waves in fluid, only 0.1% of the force is normally transmitted.) Middle ear components convert large amplitude, low force input into low amplitude, high force output. (The middle ear matches low impedance input to high impedance output.)

Note: The tympanic membrane occupies a large area and undergoes a large excursion, offering low resistance to being vibrated (by air pressure waves). The membrane of the oval window has a small area and makes small excursions against high resistance load (it must push against incompressible perilymph fluid and the round window. The ossicles form a lever system that collects energy from the large tympanic membrane and focuses it on the small oval window membrane (yielding a 60-fold force gain in the cat).

Inner ear:

The inner ear consists of the **cochlea** and vestibular apparatus. The cochlea is a component of osseous labyrinth that contains perilymph and the cochlear duct. The cochlear duct is a component of membranous labyrinth and contains endolymph.

The cochlea makes 3.25 turns in the dog (2.5 in man) around a core of bone (called the modiolus) through which the cochlear nerve passes. The entire complex resembles a snail's shell (whence the term cochlea is derived).

Within the cochlea, the **cochlea duct** (scala media) separates two perilymph chambers: the **scala vestibuli**, which contacts the oval window membrane, and the **scala tympani**, which contacts the round window membrane.

Perilymph can flow from one scala to the other through an opening (helicotrema) at the apex of the cochlea. The helicotrema is non-functional with respect to the physiology of hearing, it merely precludes perilymph stagnation.

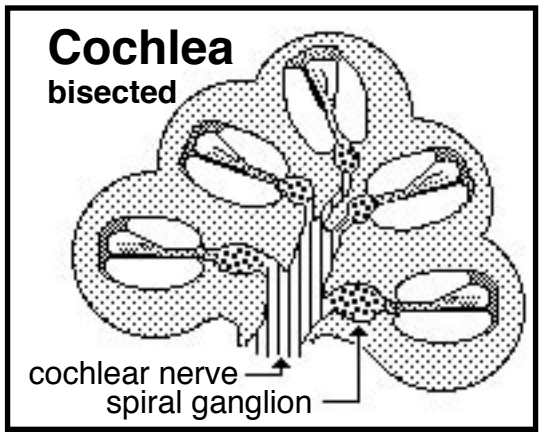

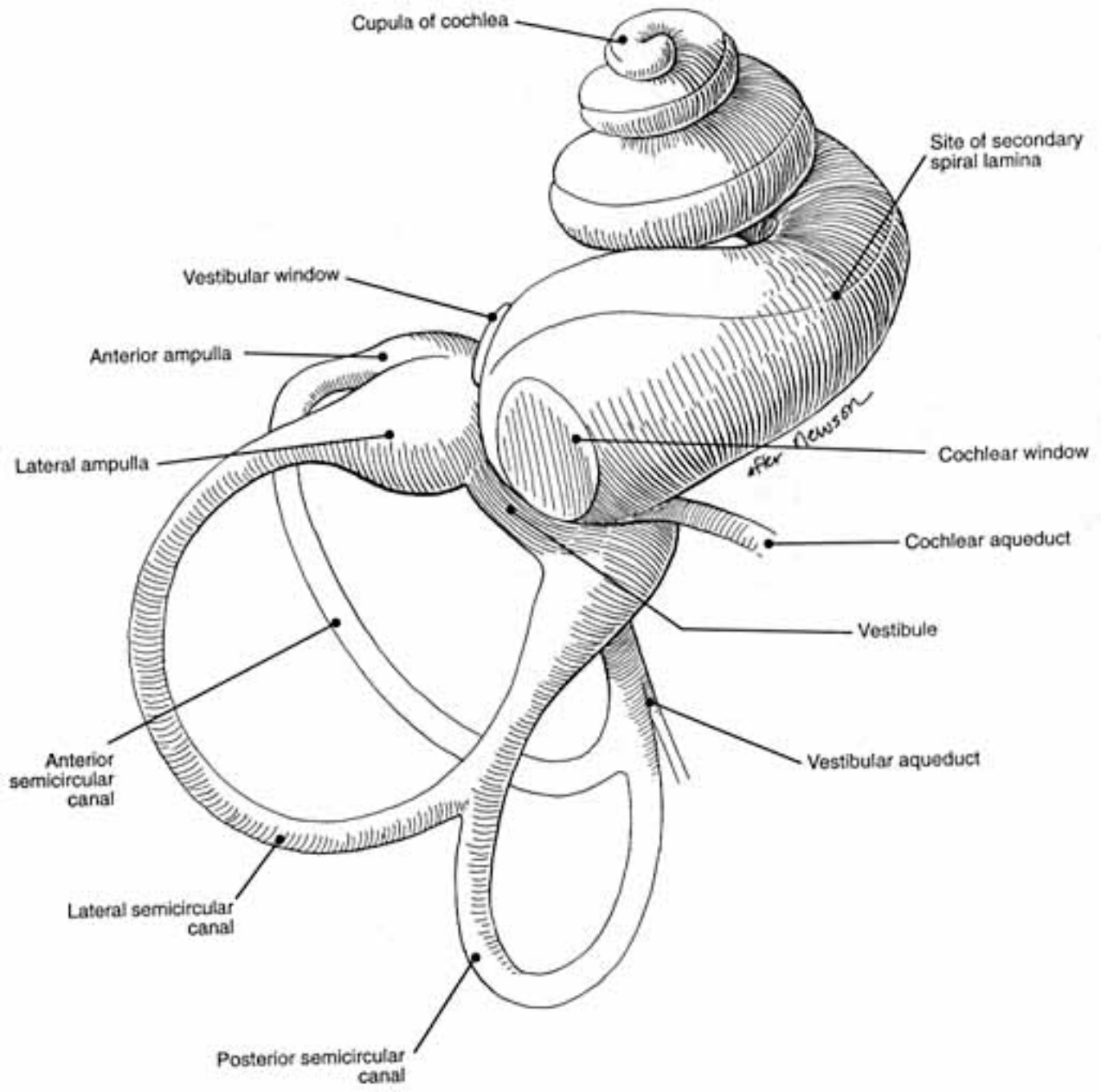
Cupula of cochlea
Site of secondary spiral lamina
Vestibular window
Anterior ampulla
Lateral ampulla
Cochlear window
Cochlear aqueduct
Vestibule
Anterior semicircular canal
Vestibular aqueduct
Lateral semicircular canal
Posterior semicircular canal

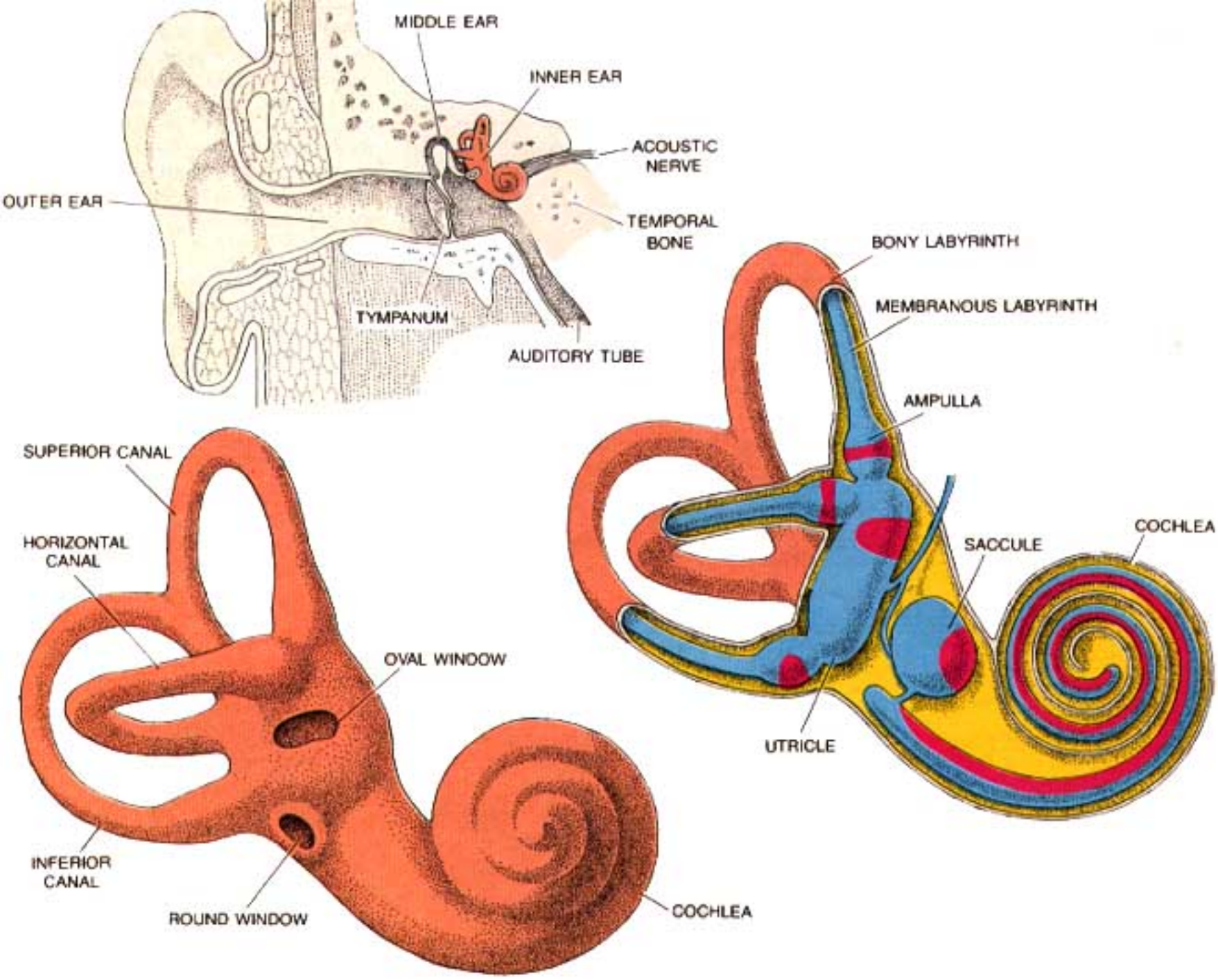
MIDDLE EAR
INNER EAR
ACOUSTIC NERVE
OUTER EAR
TEMPORAL BONE
TYMPANUM
AUDITORY TUBE
BONY LABYRINTH
MEMBRANOUS LABYRINTH
AMPULLA
SUPERIOR CANAL
HORIZONTAL CANAL
SACCULE
COCHLEA
OVAL WINDOW
UTRICLE
INFERIOR CANAL
ROUND WINDOW
COCHLEA

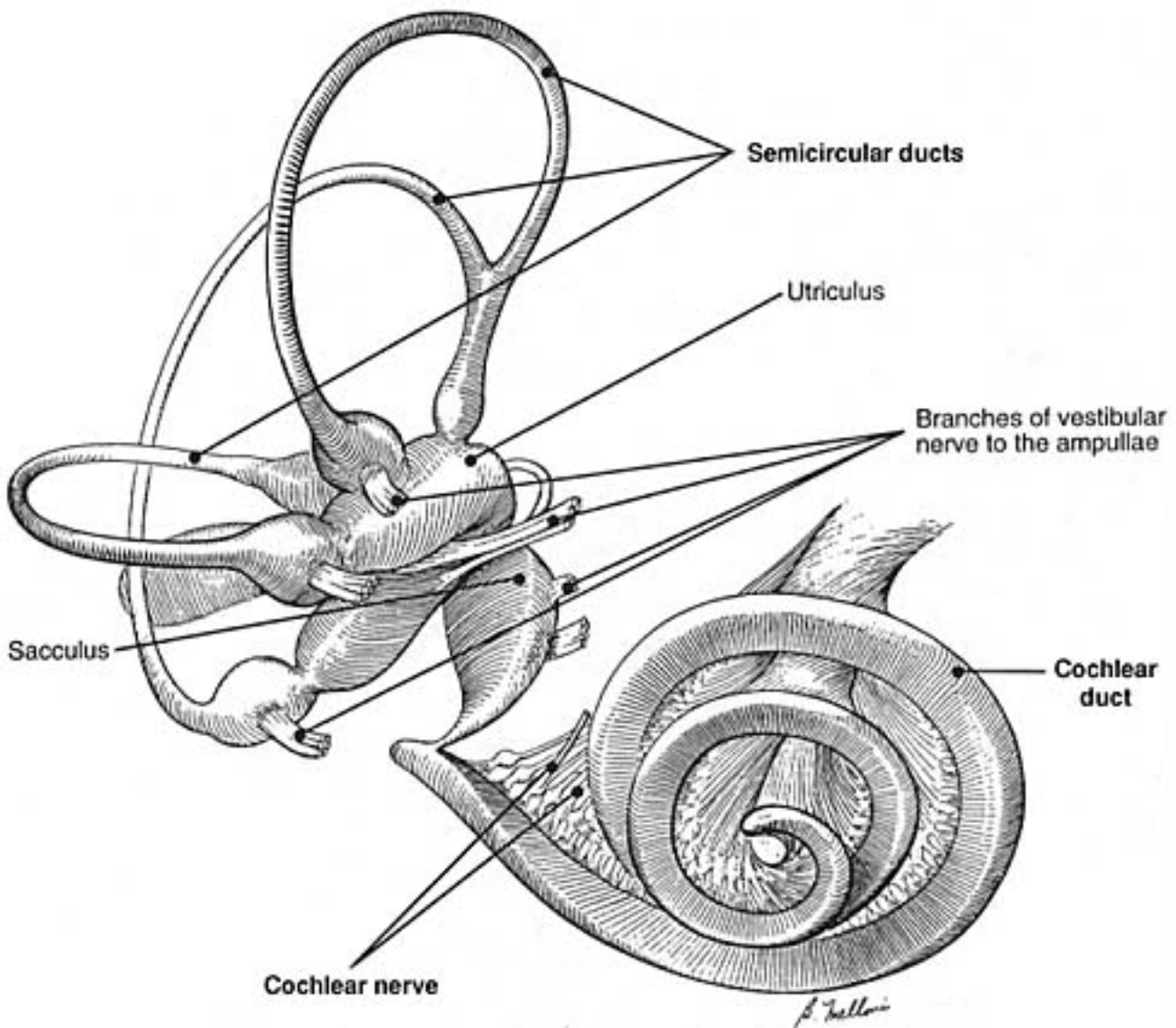
Semicircular ducts
Utriculus
Branches of vestibular nerve to the ampullae
Sacculus
Cochlear duct
Cochlear nerve

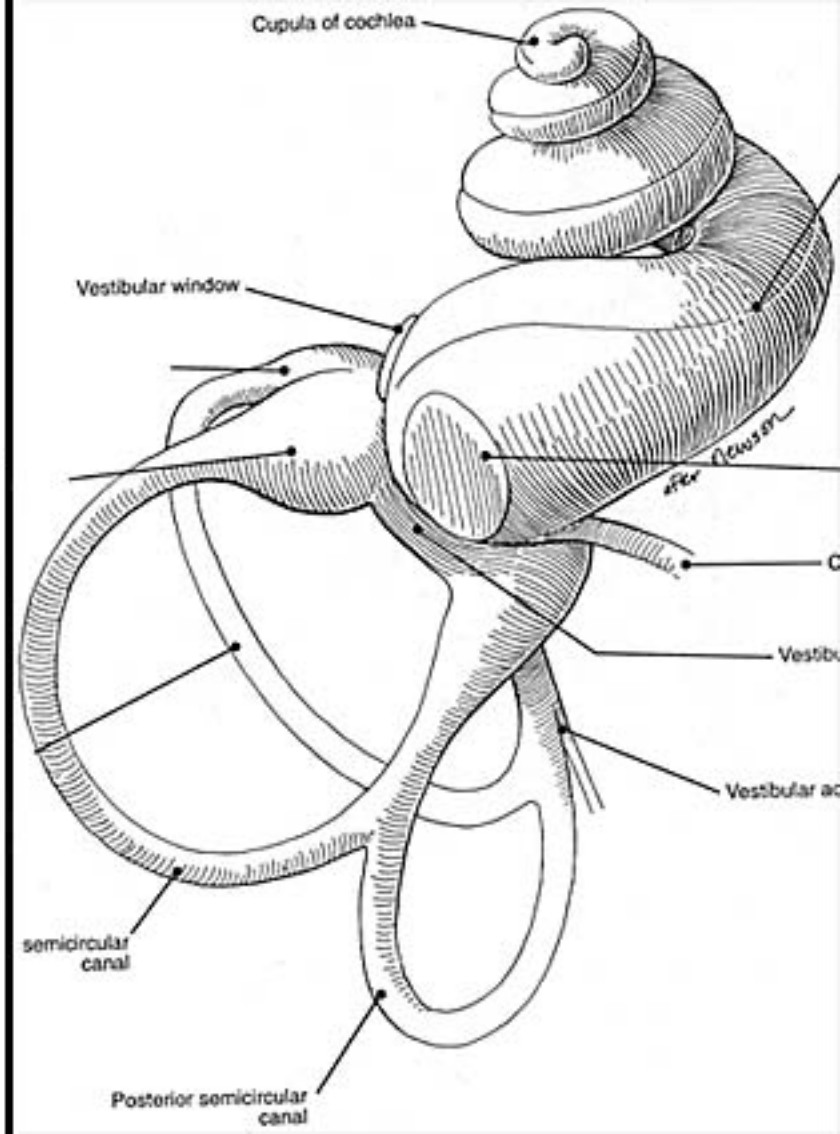
Cupula of cochlea
Vestibular window
semicircular canal
Posterior semicircular canal

APEX
Helicotrema (scala vestibuli joins scala tympani)
Apical turn
Middle turn
Basal turn
BASE
Internal acoustic meatus
Cochlear nerve
Vestibular nerve
Vestibulo-cochlear nerve (VIII)
Modiolus
From oval window
To round window
Vestibular membrane (Reissner's
Basilar membrane
Organ of Corti
ous spiral lamina

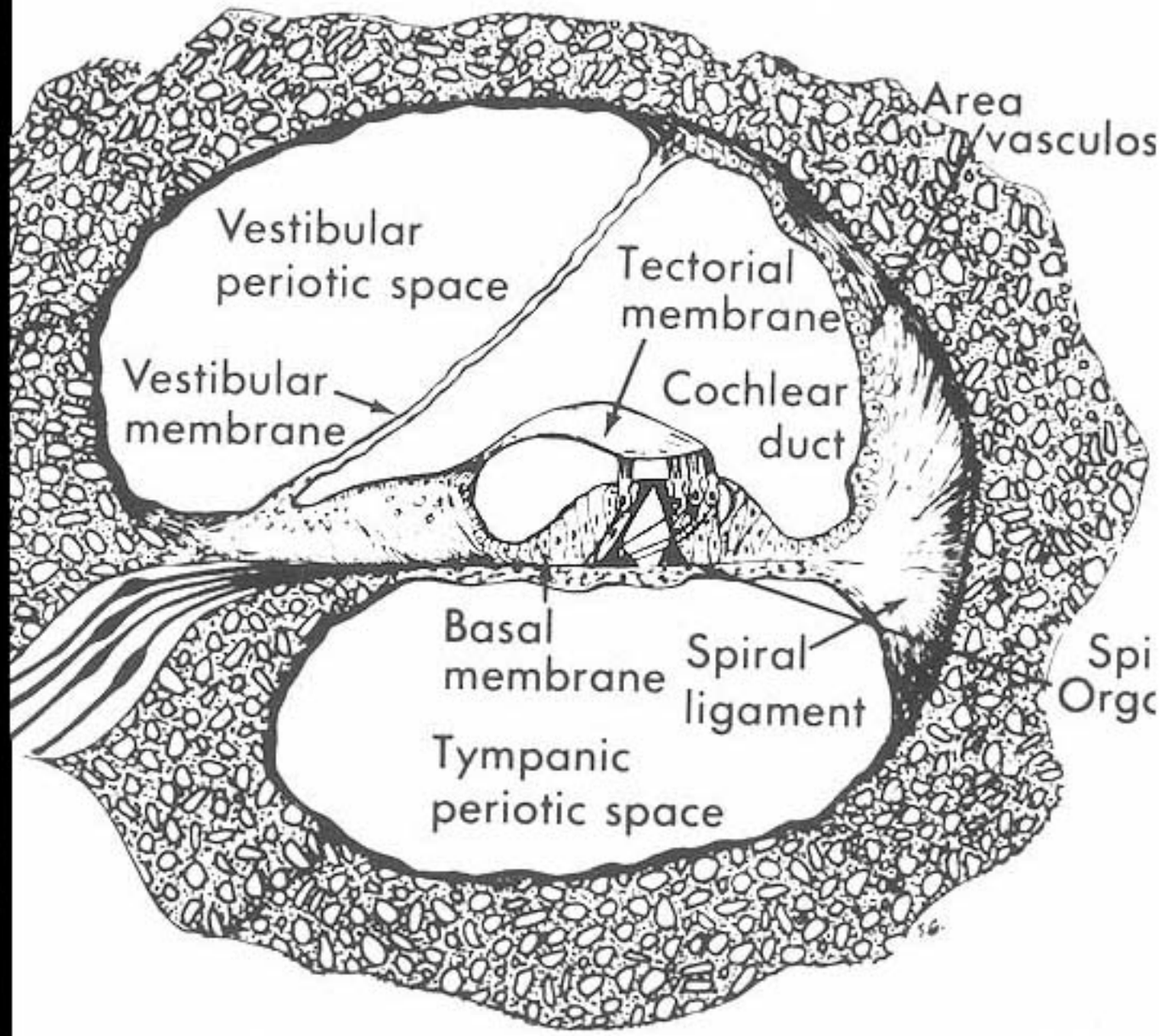
Area vasculos
Vestibular periotic space
Tectorial membrane
Vestibular membrane
Cochlear duct
Basal membrane
Spiral ligament
Tympanic periotic space

KU Medical Center

KU Medical Center

The **cochlear duct** (scala media) is triangular in cross-section. A thin vestibular membrane separates cochlear duct from scala vestibuli, presenting an ionic barrier between perilymph & endolymph. Vestibular membrane can be ignored in regard to the mechanics of hearing.

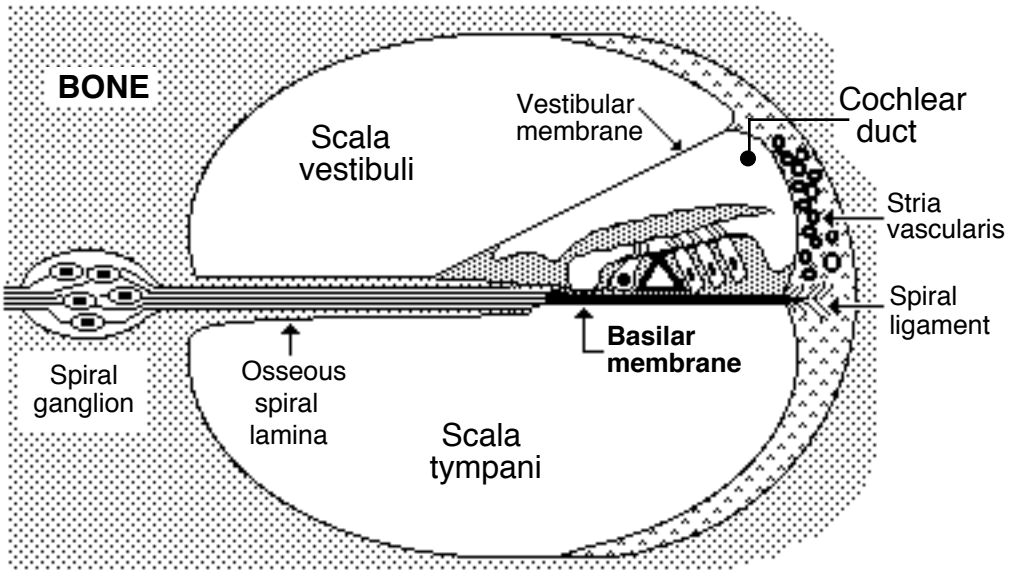

An osseous spiral lamina and basilar membrane separate cochlear duct from the scala tympani. Within the cochlear duct, a spiral organ sits atop the basilar membrane along its entire length from the base to the apex of the cochlea.

The **basilar membrane** is critical in the physiology of hearing. It consists of radial fibers that extend outward from the osseous spiral lamina. The fibers are shortest and stiffest at the base of the cochlea and they are longest at the apex. (Conversely, the osseous spiral lamina, a spiral ledge that projects outward from the modiolus, is longest at the base and shortest at the apex of the cochlea.)

The **spiral organ** (organ of Corti) features **receptor cells** (hair cells) arranged along one inner row and three outer rows. Each **hair cell** has dozens of stereo-cilia on its free surface. Hair cells are held in place by a reticular membrane (plate) anchored to the basilar membrane. Stereo-cilia project above the reticular plate, making contact with a tectorial membrane. The **tectorial membrane** arises from the limbus, a tissue mass set solidly on the osseous spiral lamina.

Afferent neurons of the **cochlear nerve** have bipolar cell bodies located in a **spiral ganglion**, within the modiolus. From the spiral ganglion, axons traverse the osseous spiral lamina. More than 90% of the axons synapse on inner hair cells. Less than 10% of the axons synapse on outer cells, which have mostly a mechanical function adjusting the position of the tectorial membrane via cellular elongation.

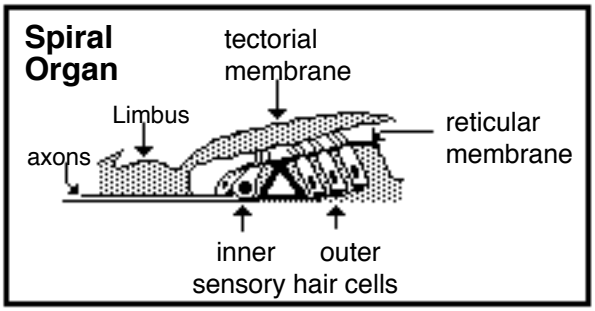

Centrally, axons leave the spiral ganglion and pass through the center of the modiolus to form the cochlear division of the vestibular-cochlear nerve. In the brain, axons synapse in dorsal and ventral cochlear nuclei.

The cochlear nerve also contains inhibitory efferent axons (from *dorsal nucleus of the trapezoid body*) that synapse on dendritic endings of afferent neurons and on outer hair cells. Via efferent axons, the brain selectively "tunes" ear sensitivity (attention) to different ranges of sound pitch.

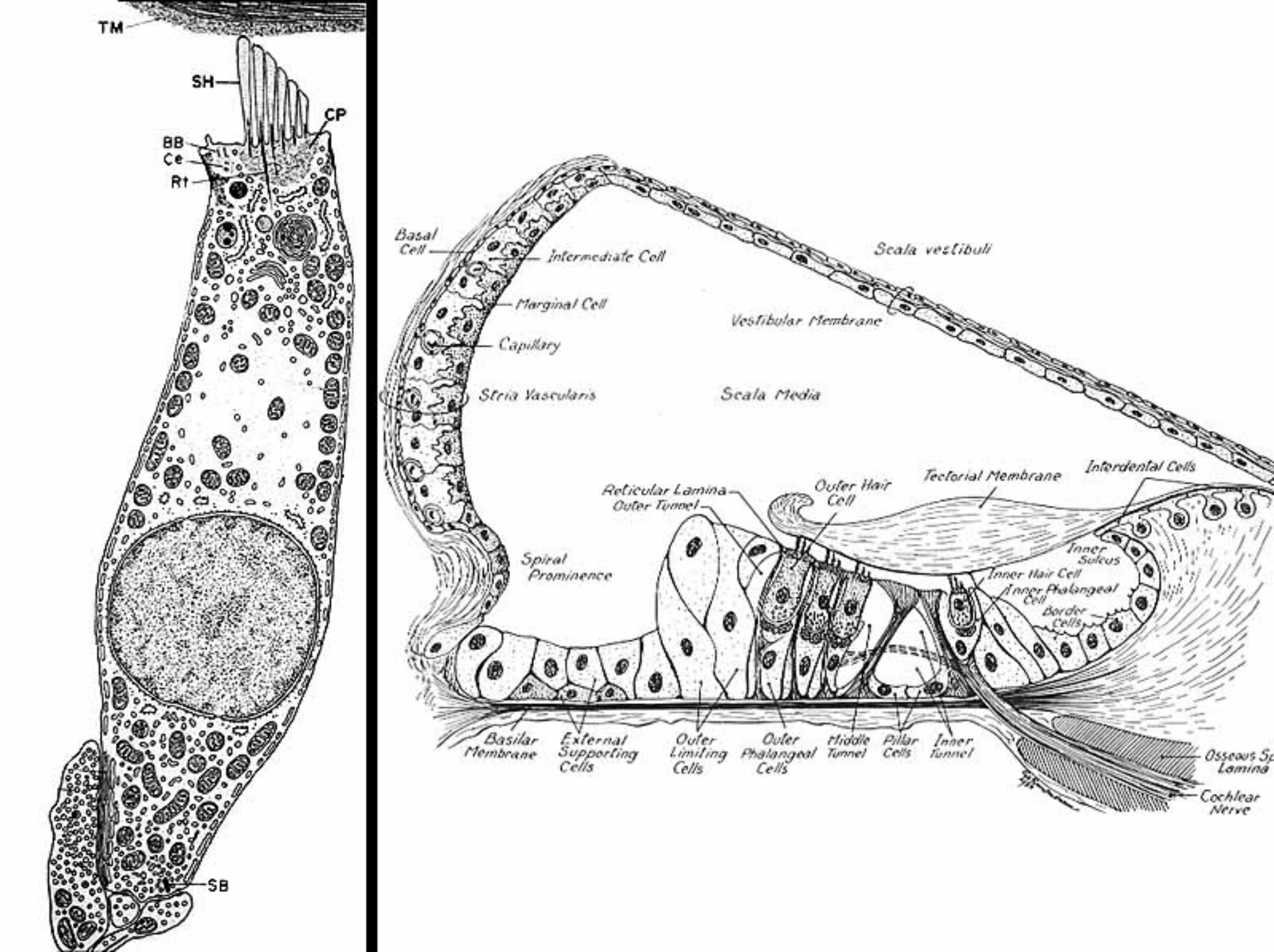
TM
SH
CP
BB
Ce
Rt
SB
Basal Cell
Intermediate Cell
Marginal Cell
Capillary
Stria Vascularis
Scala vestibuli
Vestibular Membrane
Scala Media
Reticular Lamina
Outer Tunnel
Outer Hair Cell
Tectorial Membrane
Interdental Cells
Spiral Prominence
Inner Sulcus
Inner Hair Cell
Inner Phalangeal Cell
Border Cells
Basilar Membrane
External Supporting Cells
Outer Limiting Cells
Outer Phalangeal Cells
Middle Tunnel
Pillar Cells
Inner Tunnel
Osseous Spiral Lamina
Cochlear Nerve

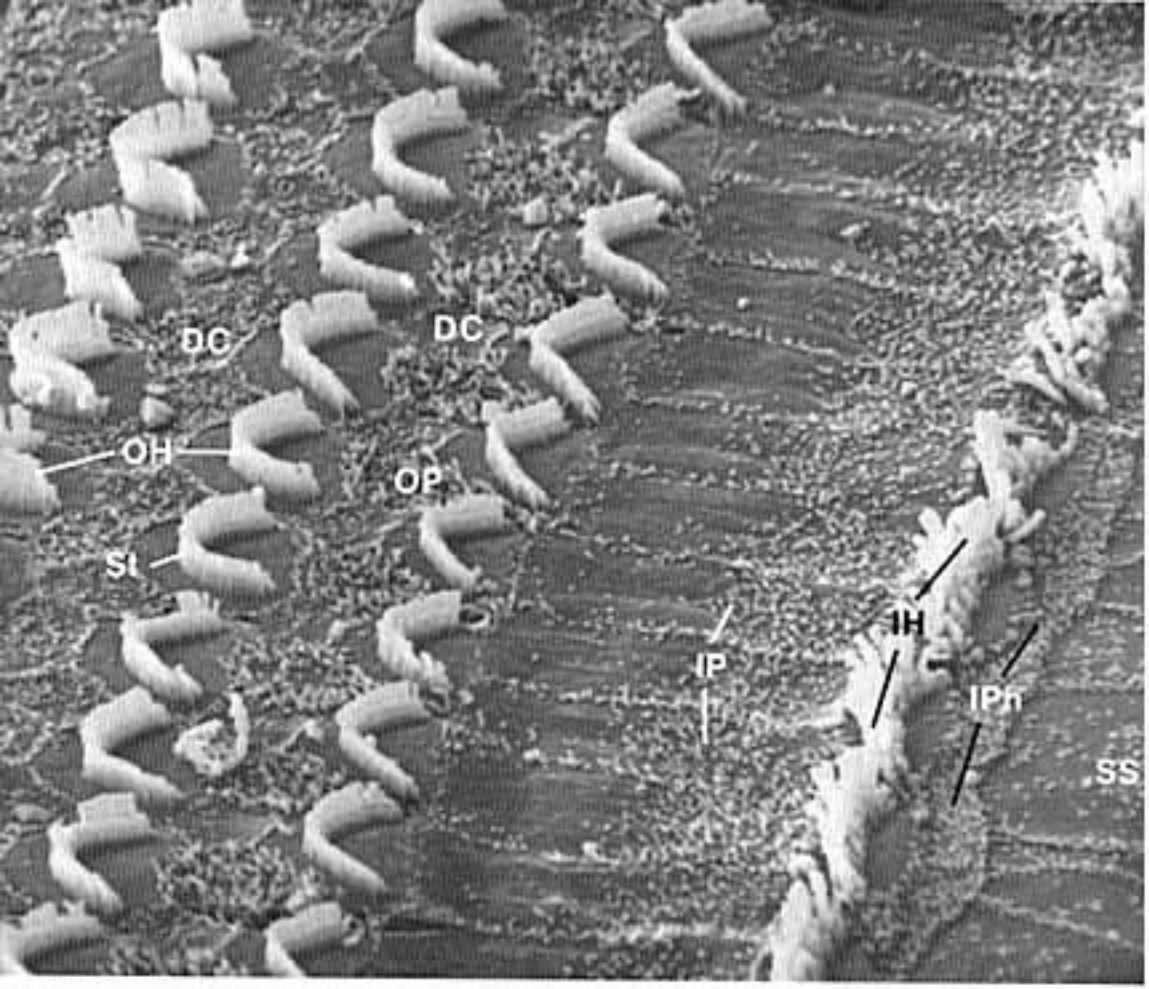
DC
DC
OH
OP
St
IP
IH
IPh
SS

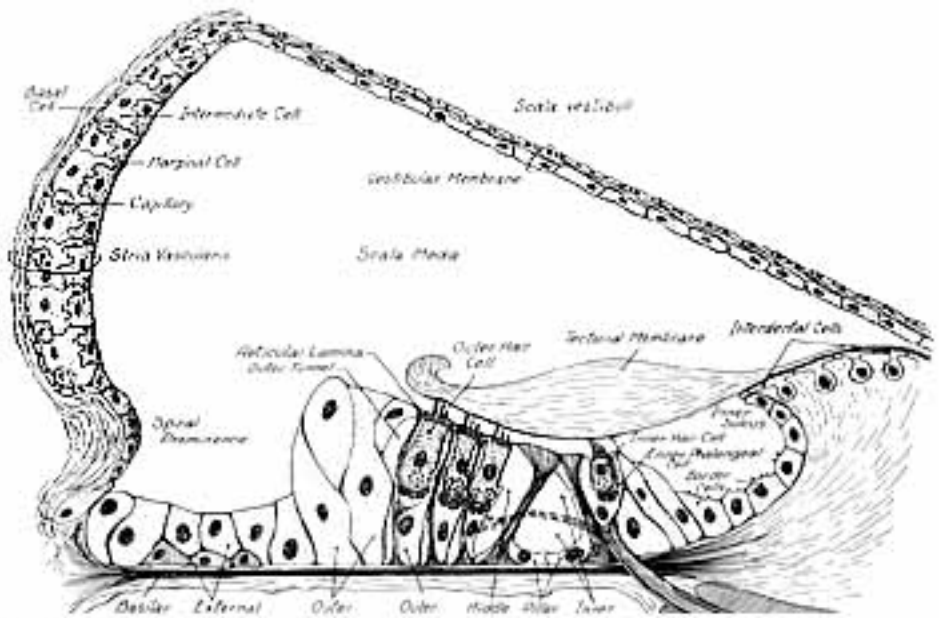
Basal Cell
Intermediate Cell
Scala vestibuli
Marginal Cell
Vestibular Membrane
Capillary
Stria Vascularis
Scala Media
Reticular Lamina
Outer Hair Cell
Tectorial Membrane
Interdental Cell
Spiral Prominence
Basilar
External
Outer
Outer
Middle
Pillar
Inner

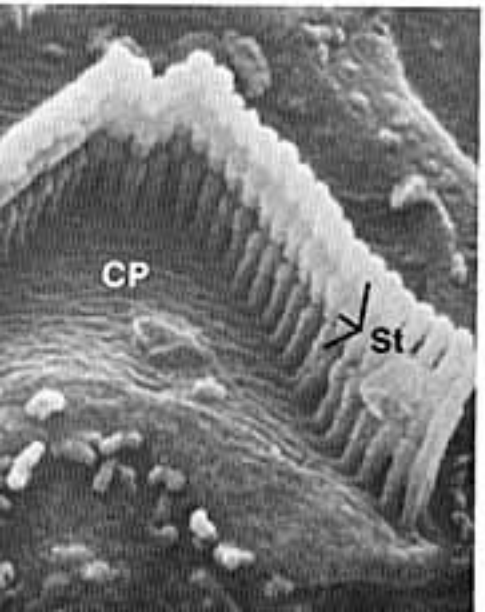
CP
St


St

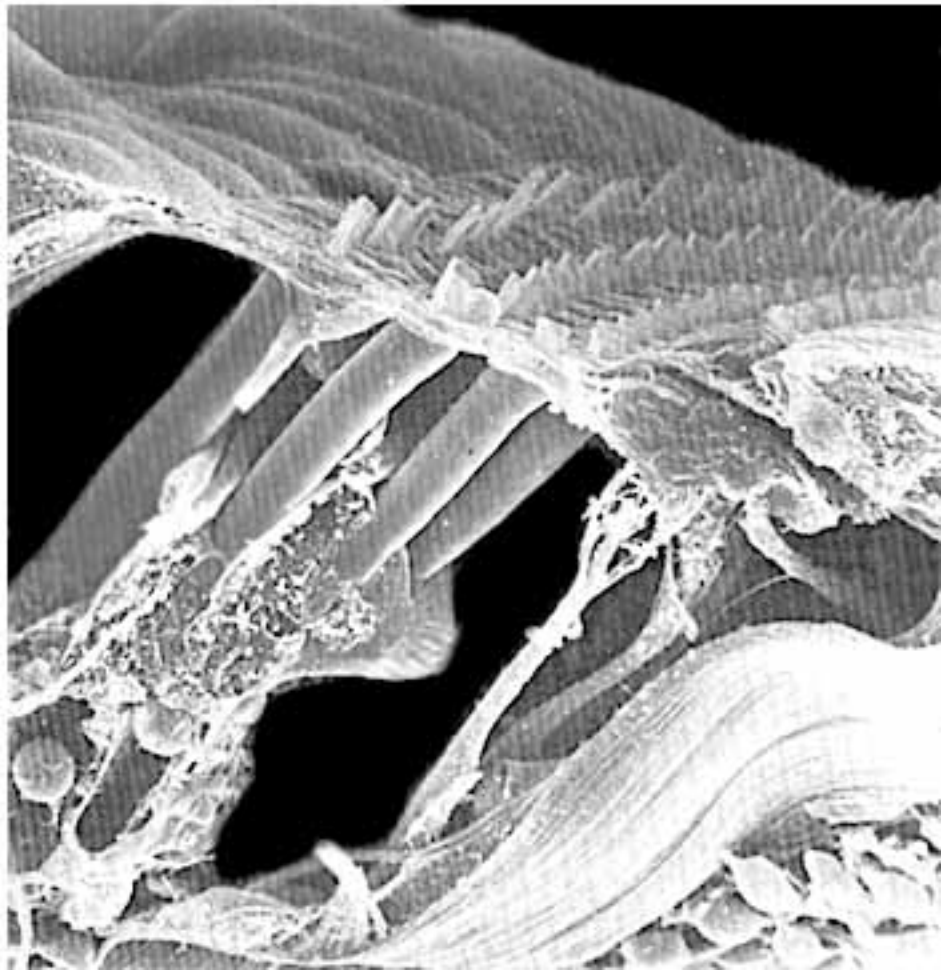

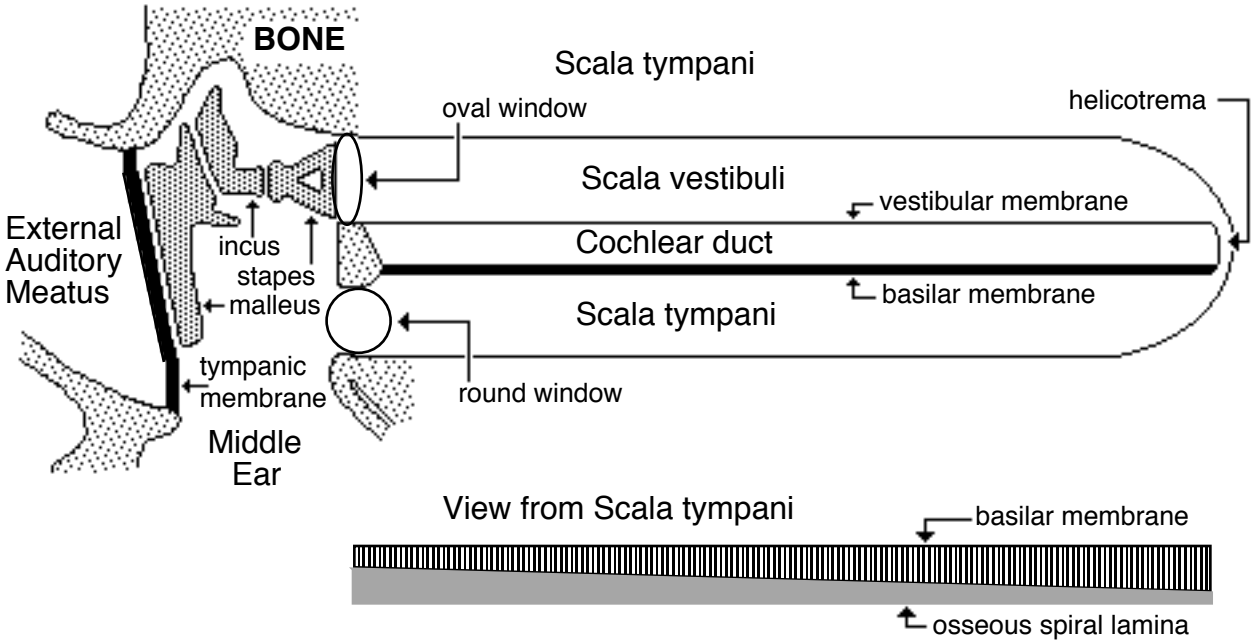

Mechanics of Hearing

Hearing begins with pressure waves impacting the tympanic membrane, causing it to vibrate. The vibration is transmitted from malleus to incus to stapes. The stapes rocks in & out, causing the membrane of the oval window to produce pressure waves within perilymph of the scala vestibuli. Pressure is transmitted without lost to endolymph in the cochlear duct (the vestibular membrane offers no resistance to fluid pressure). The pressure wave displaces the basilar membrane, transmitting pressure to the scala tympani and displacing the membrane of the round window.

As a pressure wave travels from the base to the apex of the cochlea, displacement to the basilar membrane is greatest where the membrane is resonant to the frequency of the traveling wave. High frequency traveling waves cause displacement at the base of the cochlear and low frequency waves travel to the apex of the cochlea.

Movement of the basilar membrane imparts a rocking action, proportional to degree of displacement, to the spiral organ which rests upon the membrane. Cilia, in contact with the stationary tectorial membrane, are displaced relative to the moving hair cells. The tectorial membrane doesn't rock because it is attached to the limbus, which sits on bone (osseous spiral lamina).

Cilia displacement (in one direction) opens K^+ channels leading to depolarization of hair cells, release of glutamate neurotransmitter, depolarization of dendrites that synapse on the hair cells, and increased frequency of action potentials in the cochlear nerve. Cilia displacement in the other direction results in hyperpolarization and decreased frequency of action potentials.

Thus, cilia displacement modulates an on-going K^+ current from the endolymph through the hair cell to the perilymph. Hair cell excitability modulates actions potentials in the cochlear nerve.

Note: A common cause of deafness with advanced age is localized bone deposition that impedes the rocking action of the stapes. This is called conduction deafness and it can be treated by a hearing aid that amplifies sound or imparts vibration to perilymph through temporal bone contact.

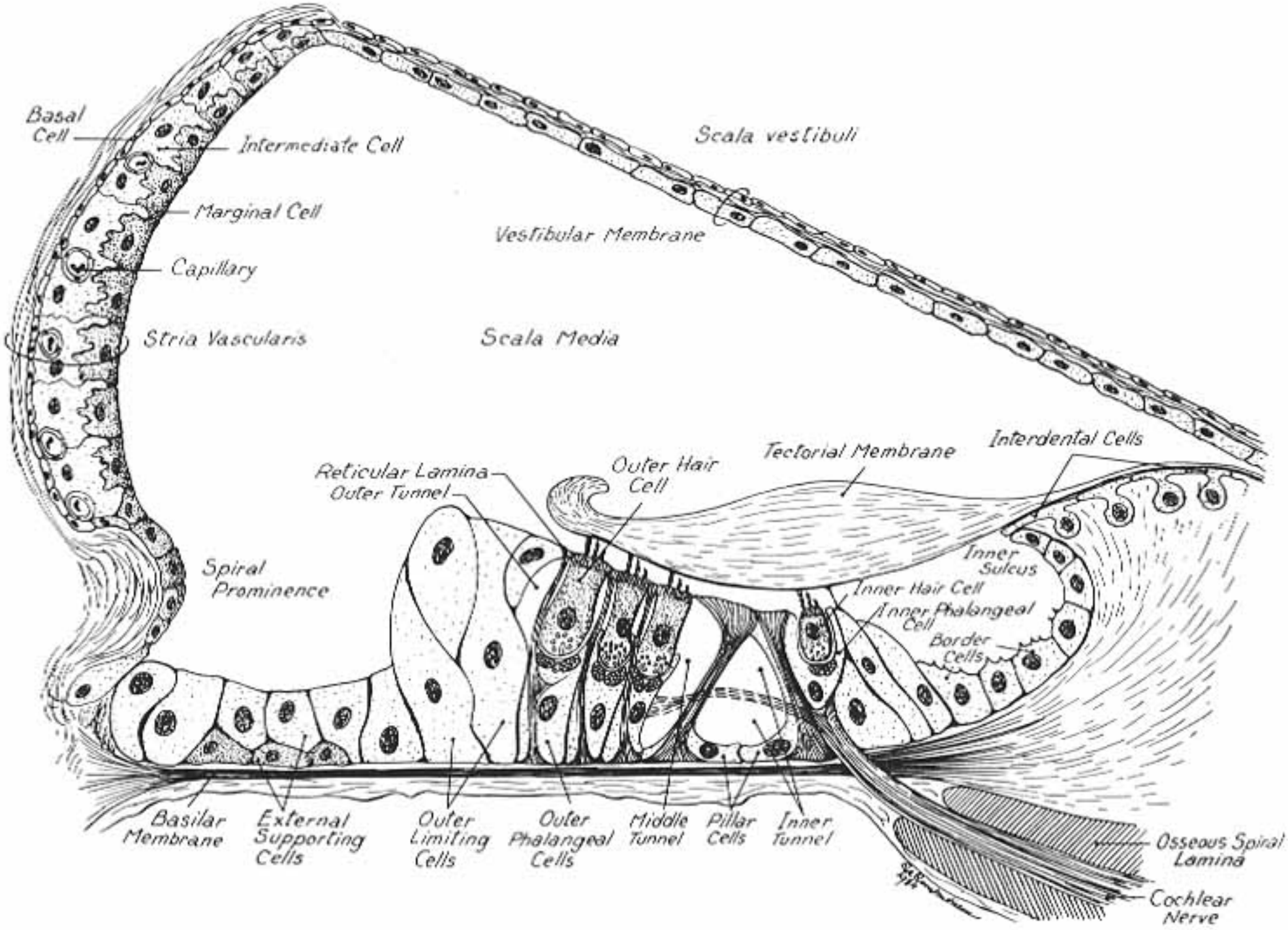
Basal Cell
Intermediate Cell
Marginal Cell
Capillary
Stria Vascularis
Scala vestibuli
Vestibular Membrane
Scala Media
Reticular Lamina
Outer Tunnel
Outer Hair Cell
Tectorial Membrane
Interdental Cells
Spiral Prominence
Inner Sulcus
Inner Hair Cell
Inner Phalangeal Cell
Border Cells
Basilar Membrane
External Supporting Cells
Outer Limiting Cells
Outer Phalangeal Cells
Middle Tunnel
Pillar Cells
Inner Tunnel
Osseous Spiral Lamina
Cochlear Nerve

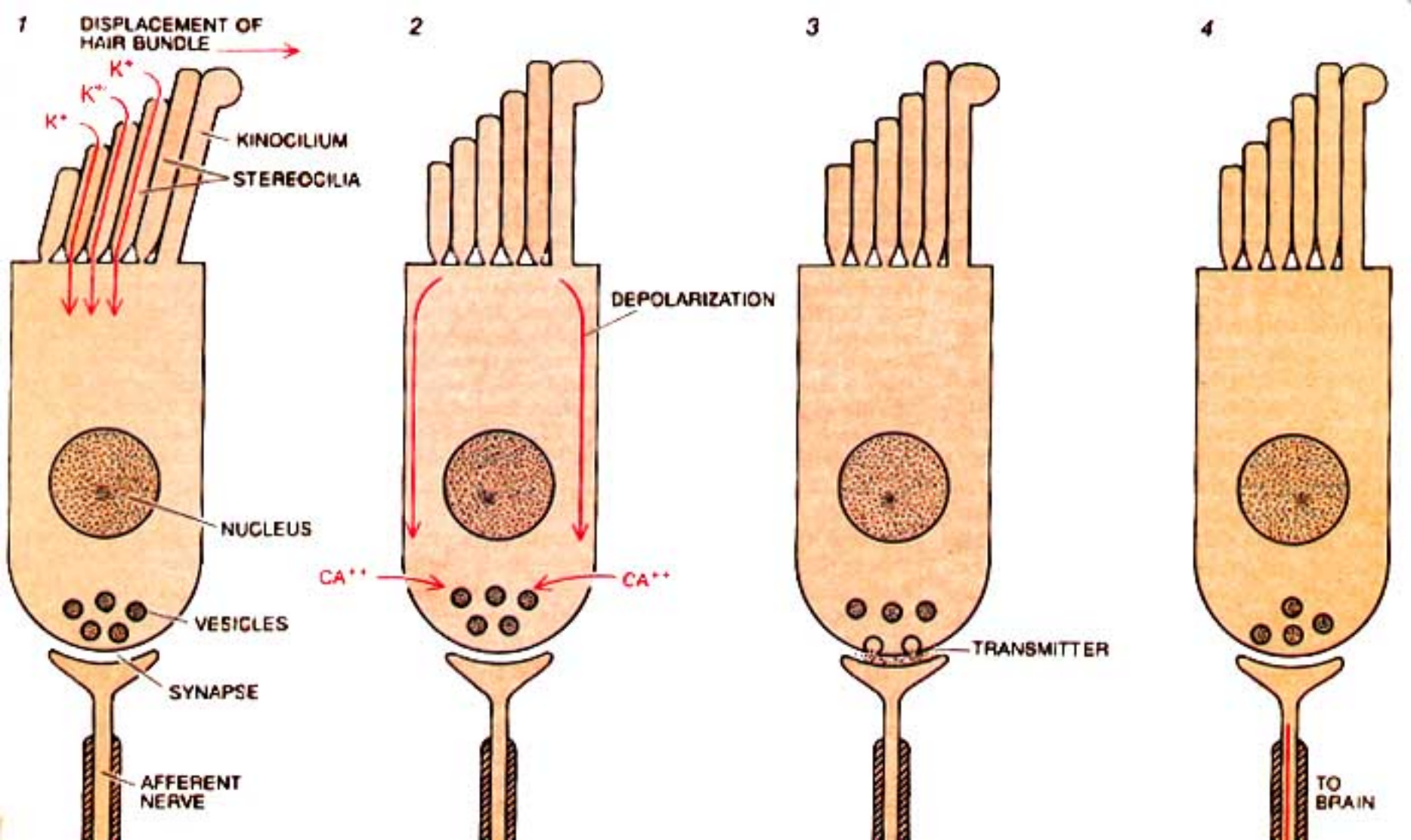
1
DISPLACEMENT OF HAIR BUNDLE
K+
K+
K+
KINOCILIUM
STEREOCILIA
NUCLEUS
VESICLES
SYNAPSE
AFFERENT NERVE
2
DEPOLARIZATION
CA++
CA++
3
TRANSMITTER
4
TO BRAIN

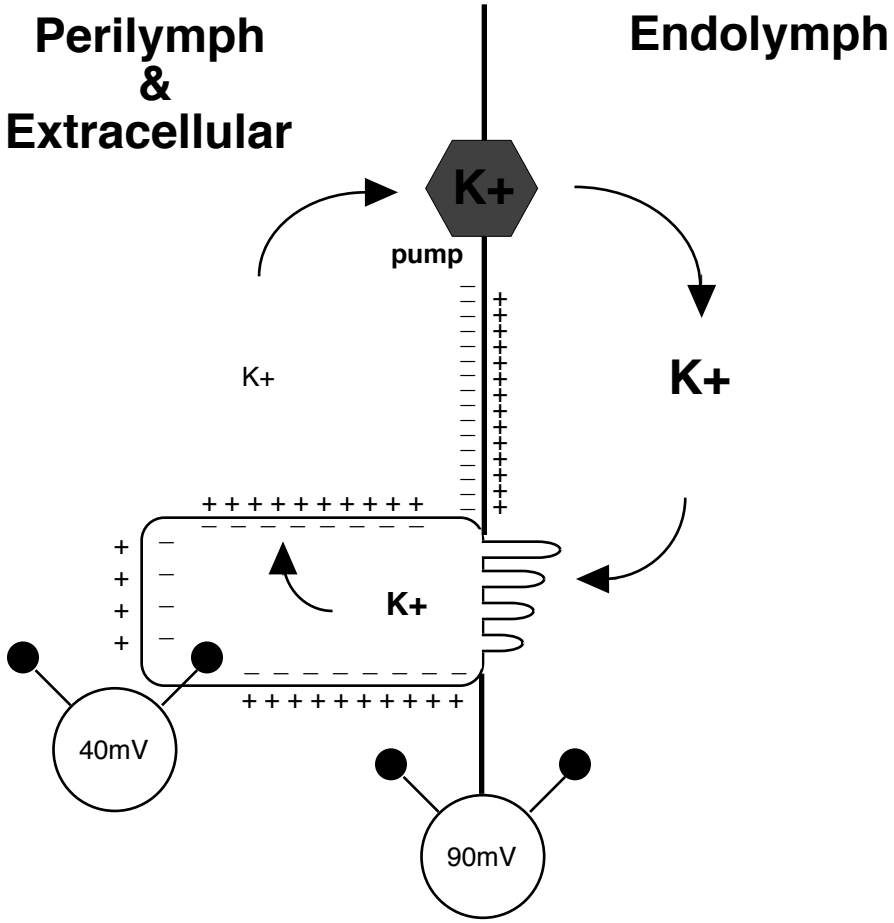

Pressure waves of air (20 to 20,000 Hz in man; up to 40,000 Hz in the dog &100,000 Hz in the bat) can be interpreted as sound. Sound has subjective properties that correspond to parameters of physics:

pitch = wave frequency = Hz = Hertz = cycles/sec.,

volume = amplitude from the low point to the high point in a pressure wave, and

direction = location of the source of the sound waves.

(Sound also has "color"— higher frequencies impart overtones which enable one to distinguish different instruments playing the same note at the same volume.)

Pitch — the brain deciphers pitch by determining which fibers of the cochlear nerve (which hair cells of the spiral organ; what place along the basilar membrane) are maximally active (for > 200 Hz). As the pitch (Hz) of a sound increases, the peak amplitude of basilar membrane displacement regresses, from the apex (longest fibers) toward the base (shortest fibers) of the cochlea. (*Place principle*: pitch is determined by the place of maximal amplitude displacement along the basilar membrane.)

Volume — the brain interprets volume as a function of the number of axons firing and the frequency of their action potentials. Increased volume (amplitude) will result in greater excursion of the basilar membrane, greater displacement of cilia, greater depolarization of receptor cells, and higher frequencies of action potentials in more cochlear nerve axons (whatever the pitch pattern of basilar membrane displacement).

Direction — at low frequencies, the brain uses the phase difference (time-lag) between inputs to right and left ears to determine which ear is closer to the source of the sound; at high frequencies, the head acts as a barrier resulting in an intensity difference between the near and far ear. (Also, the pinna may modify sound coming from different directions, and the animal can move its ears and head to assist in sound localization.)

Auditory Pathway

Cochlear nerve fibers synapse in **dorsal and ventral cochlear nuclei**, typically each fiber synapses in both nuclei. The cochlear nuclei contain second-order neurons. Thereafter, the auditory pathway is bilateral and complex because of many synaptic possibilities.

We can say that more fibers decussate (in the **trapezoid body**) than remain ipsilateral, that the pathway ascends in the **lateral lemniscus** and then in the **brachium of the caudal colliculus**, and that the conscious sound pathway synapses in the **medial geniculate body**, from which neurons send their axons through the internal capsule to cerebral cortex surrounding the **sylvian sulcus** (primary auditory cortex).

Additional synaptic possibilities include: ventral nuclei of trapezoid body (gray matter among fibers of the trapezoid body); dorsal nucleus of the trapezoid body; nuclei of the lateral lemniscus; and caudal colliculus.

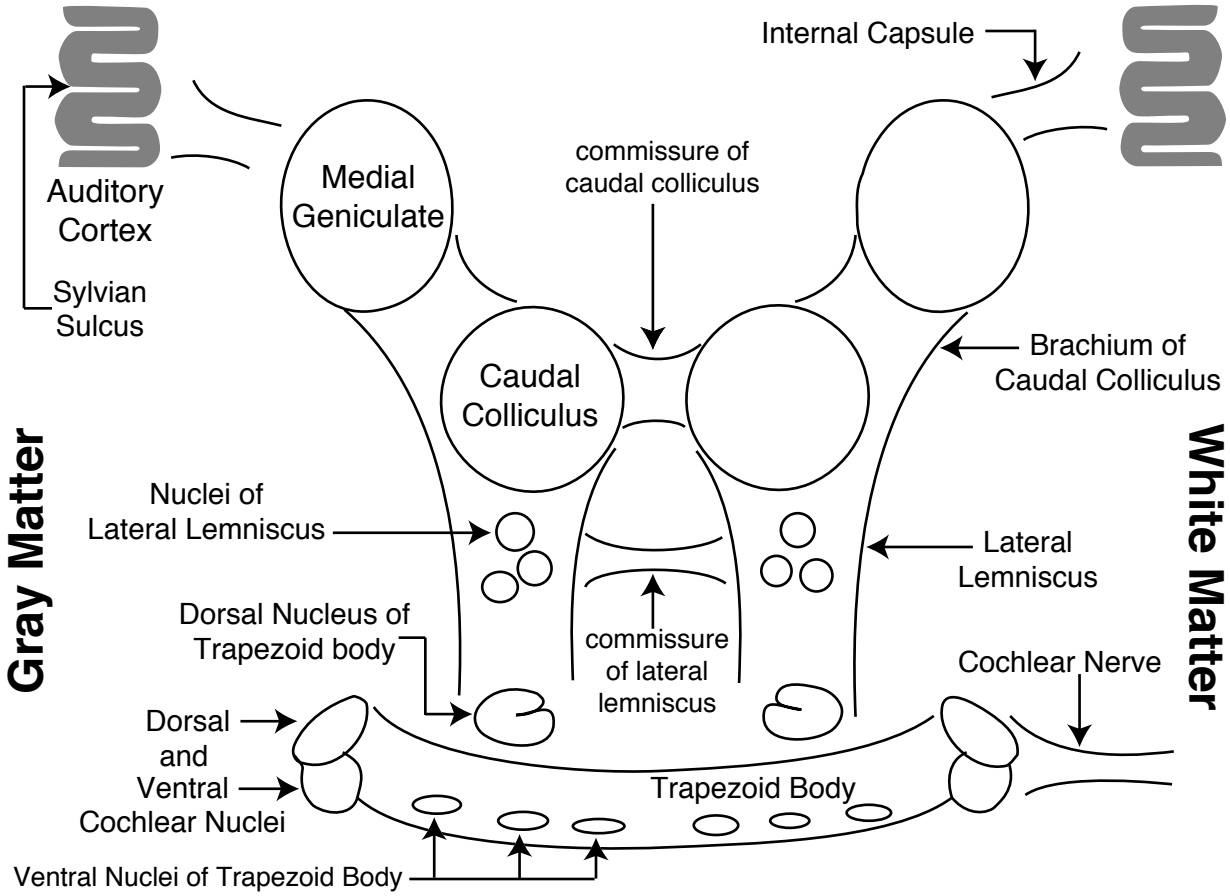

Comments about gray matter in the auditory pathway:

Cochlear nuclei (dorsal and ventral) — receive input from the ipsilateral cochlear nerve. Second-order neurons, tonotopically organized within the nucleus, are the source of all central auditory pathways. Like the cochlear nerve and the rest of the auditory pathways, second order neurons exhibit continuous background firing that is increased/decreased by sound driven excursions of the basilar membrane and spiral organ.

Lesions of cochlear nuclei (or cochlear nerve or a cochlea) produce unilateral deafness; lesions central to the cochlear nuclei affect both ears (because central pathways are bilateral).

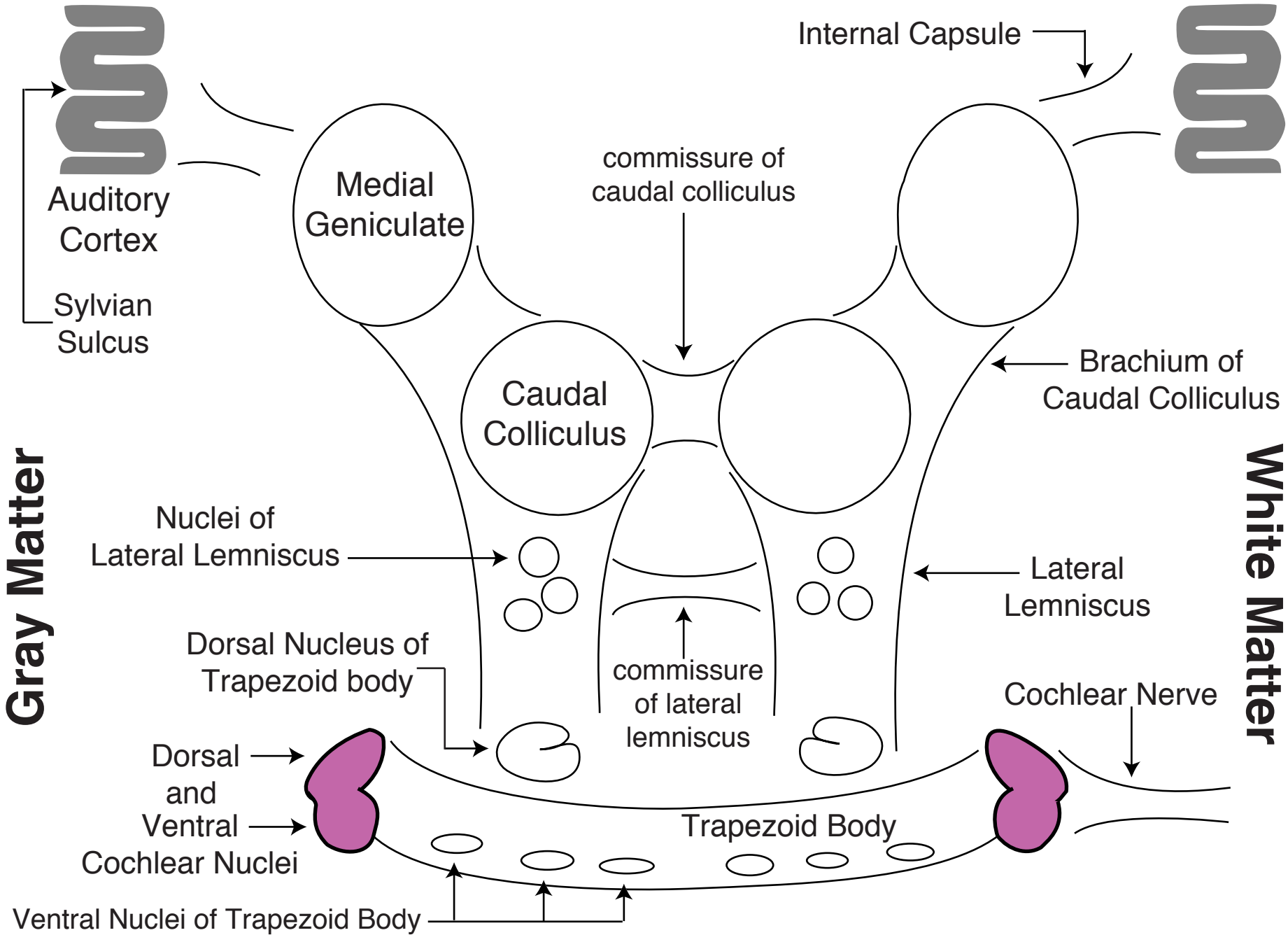
Internal Capsule
Auditory Cortex
Sylvian Sulcus
Medial Geniculate
commissure of caudal colliculus
Caudal Colliculus
Brachium of Caudal Colliculus
Gray Matter
White Matter
Nuclei of Lateral Lemniscus
Lateral Lemniscus
Dorsal Nucleus of Trapezoid body
commissure of lateral lemniscus
Cochlear Nerve
Dorsal and Ventral Cochlear Nuclei
Trapezoid Body
Ventral Nuclei of Trapezoid Body

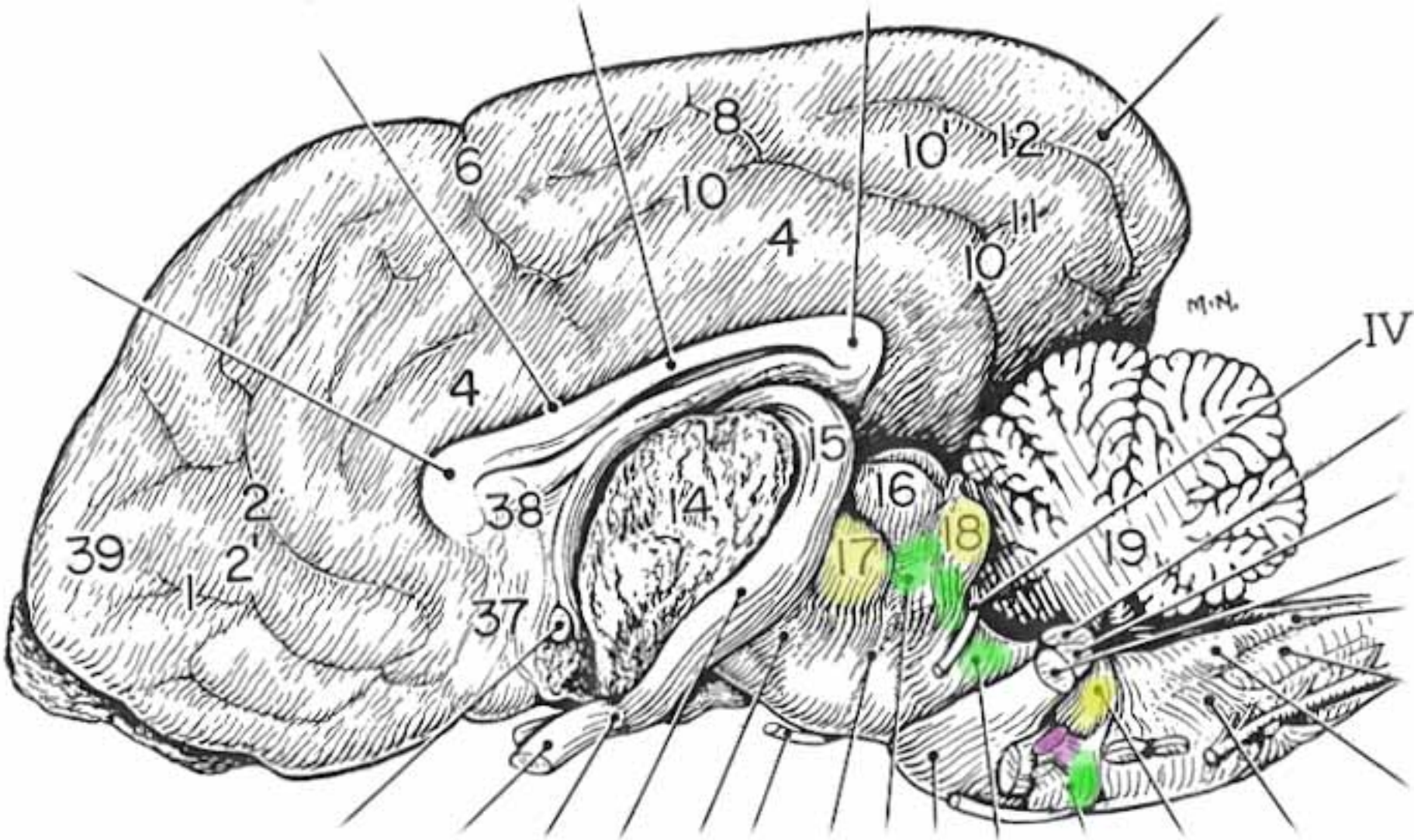

8
6
10
10'
12
11
4
10
M.N.
IV
4
15
16
38
14
2
18
17
19
39
2'
1
37

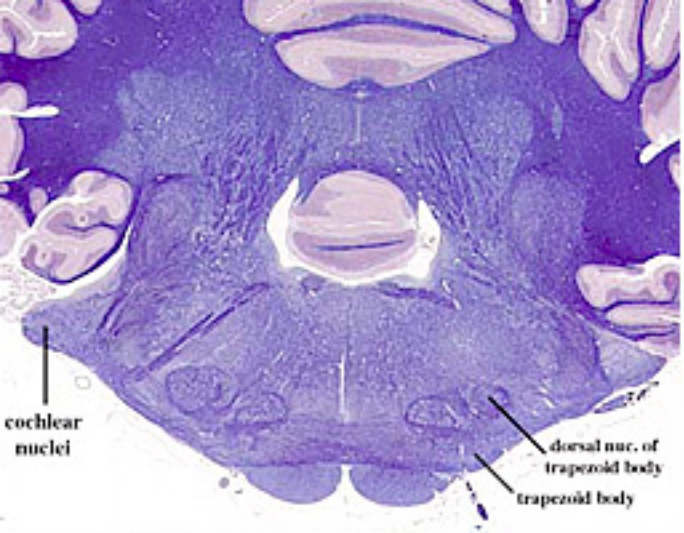
cochlear
nuclei
dorsal nuc. of
trapezoid body
trapezoid body

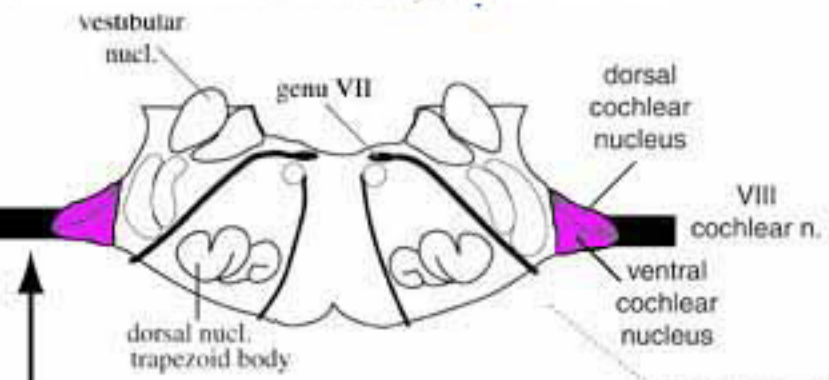
vestibular
nucl.
genu VII
dorsal
cochlear
nucleus
VIII
cochlear n.
ventral
cochlear
nucleus
dorsal nucl.
trapezoid body

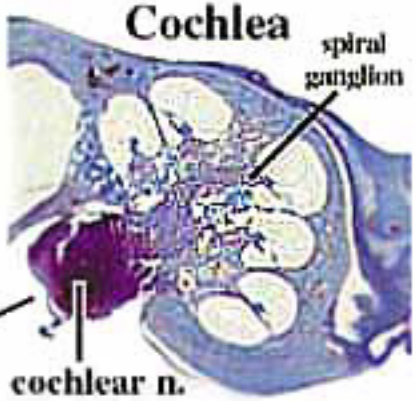
Cochlea
spiral
ganglion
cochlear n.

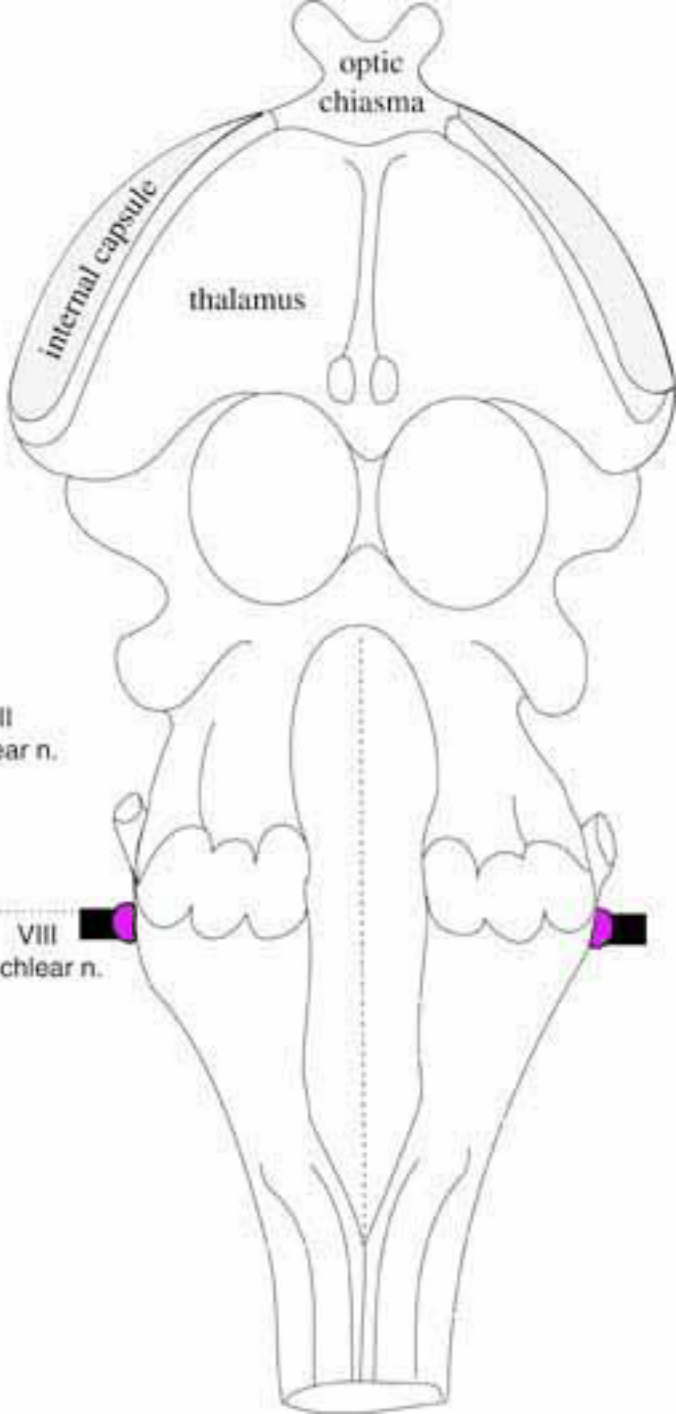
optic
chiasma
internal capsule
thalamus
VIII
cochlear n.

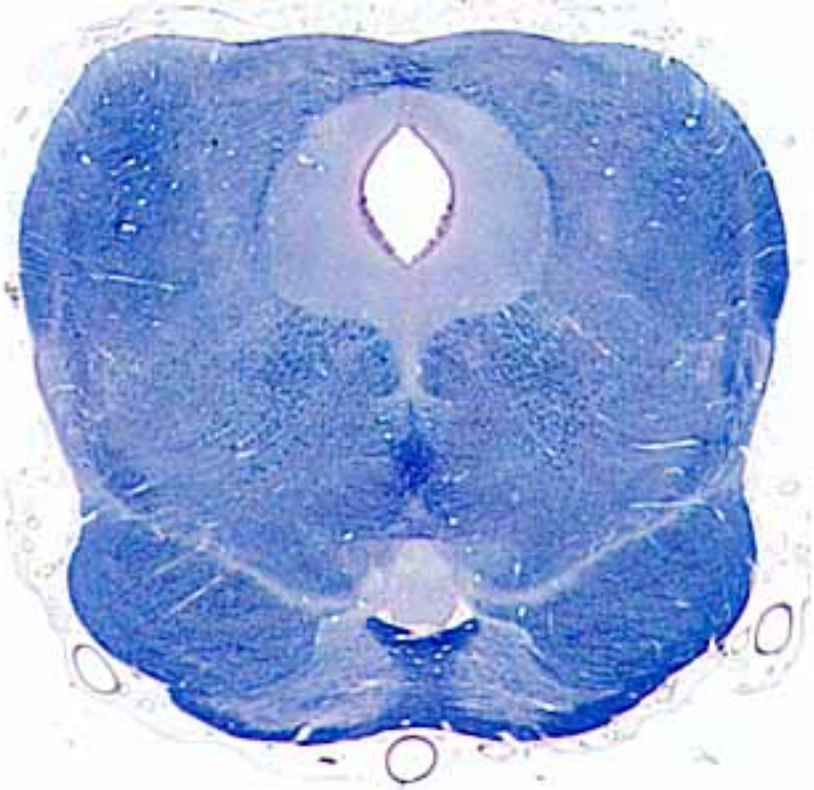

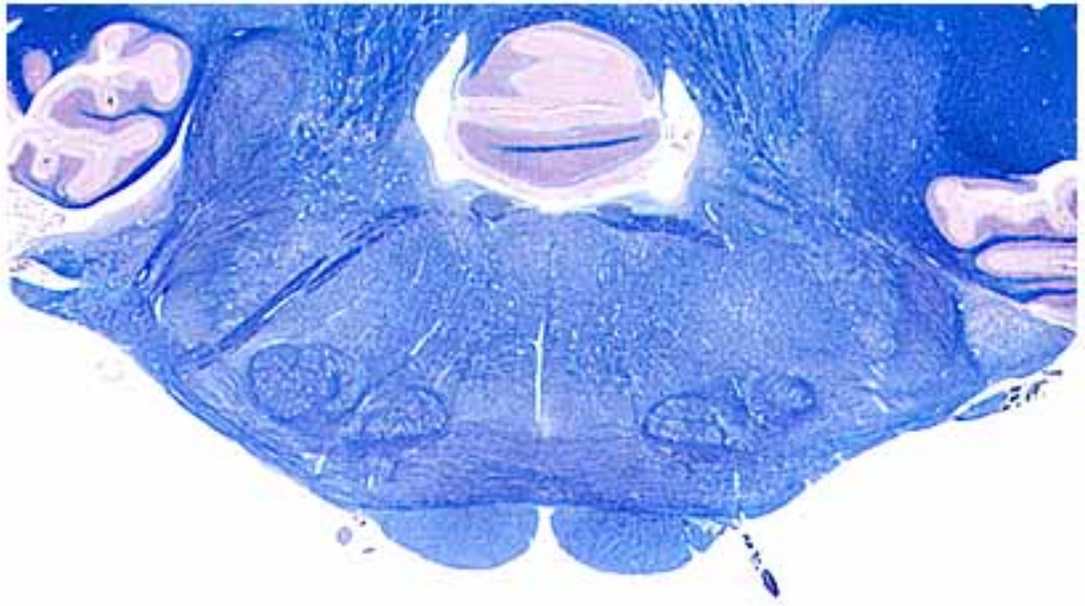

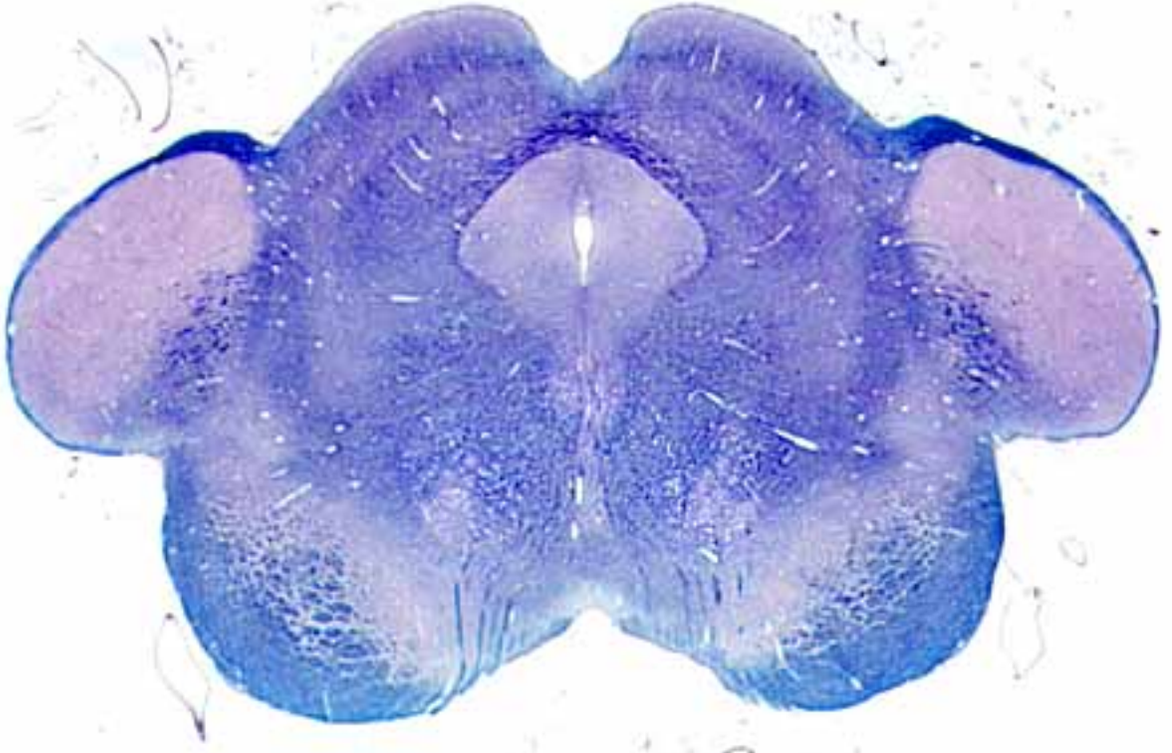

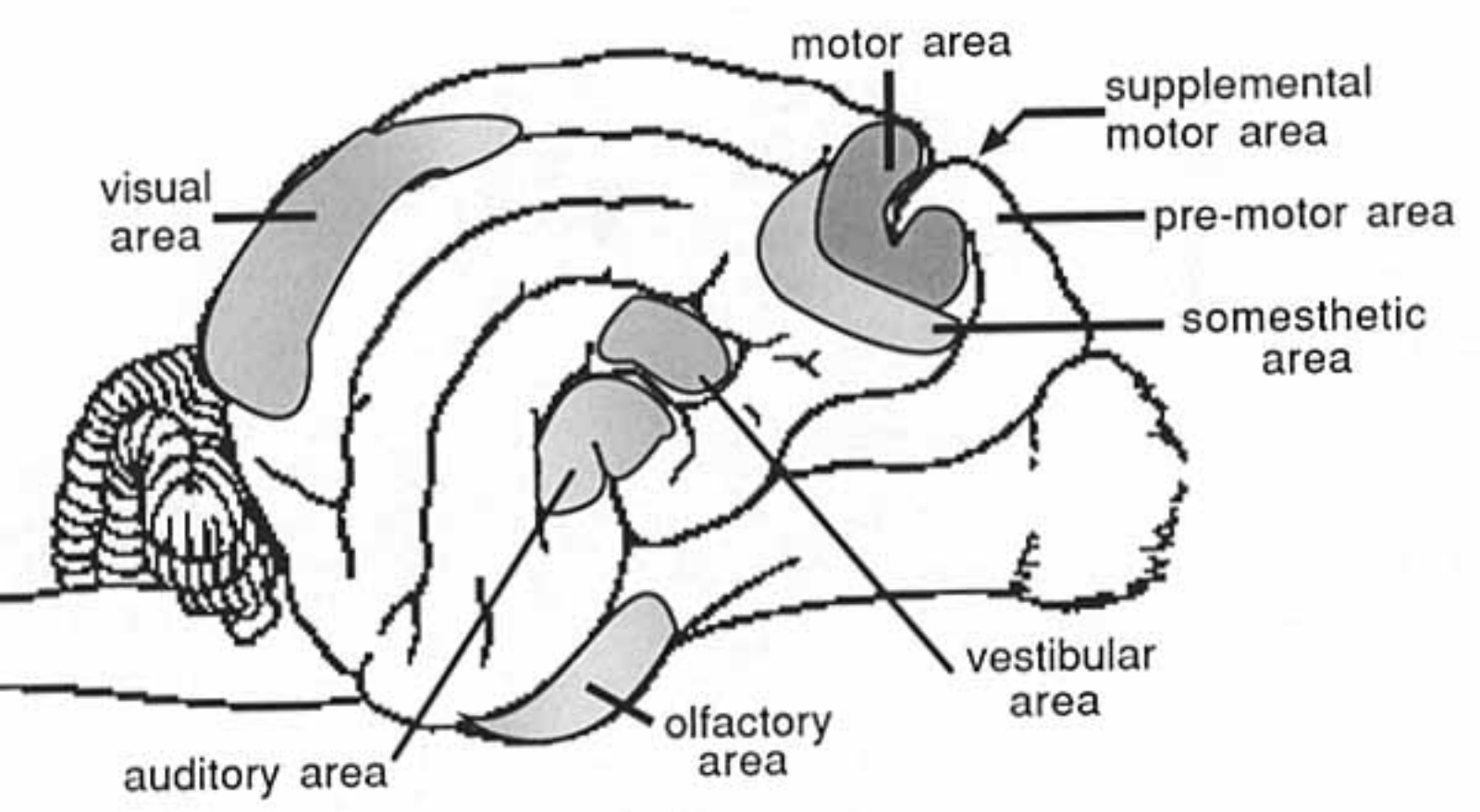
motor area
supplemental motor area
visual area
pre-motor area
somesthetic area
vestibular area
olfactory area
auditory area

Dorsal nucleus of trapezoid body — each nucleus receives input from right and left ears (via cochlear nuclei). The nucleus functions in sound localization, i.e., detecting phase and intensity differences between the two ears. (Different neurons respond to the different time lags between the two ears. Other neurons respond to different intensity differences between the two ears.)

The nucleus sends output to cranial nerves V and VII for reflex contraction of tensor tympani and stapedius muscles to dampen loud sound.

The nucleus is the source of efferent axons which selectively "tune" the spiral organ for frequency discrimination (e.g., listening to the play of one instrument within an orchestra). (Efferent innervation affects the length of outer hair cells which changes the position of the tectorial membrane which adjusts the sensitivity of inner hair cells.)

Caudal colliculus — receives input via the lateral lemniscus. The colliculus contains neurons that are sensitive to phase and intensity differences between the ears. Also, caudal colliculus neurons that project to the medial geniculate are part of a conscious auditory pathway.

Via tectospinal/tectobulbar tracts, output from the caudal colliculus produces reflex turning of the head, ears and eyes toward a sudden sound stimulus. (Collateral branches of auditory pathway axons go to the reticular formation to alert the whole brain to a loud sound stimulation.)

Medial geniculate — receives input via the brachium of the caudal colliculus. Imprecise sound consciousness takes place at the medial geniculate level.

Geniculate neurons project their axons through the internal capsule to the primary auditory cortex. (Note: The geniculate body functions for sound like the thalamus functions for tactile sense.)

Primary Auditory Cortex — located around the sylvian sulcus, this cortex is necessary for recognizing temporal patterns of sound and direction of pitch change, i.e., elements of melody, speech, etc. The cortex has separate tonotopic maps for detecting pitch and direction (pitch and direction information is relayed to the cortex by separate pathways).

Auditory association cortex surrounds the primary auditory cortex from which it receives input. The association cortex is required to extract meanings of sound patterns and associate learned significance with a particular sound pattern.

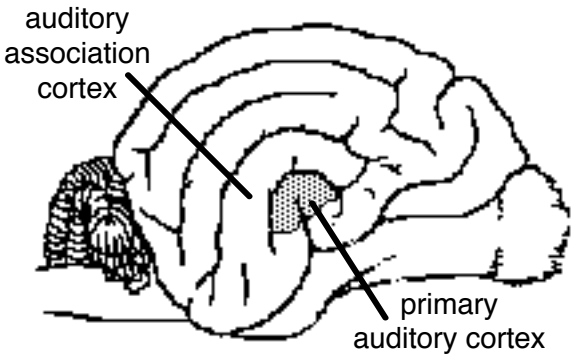

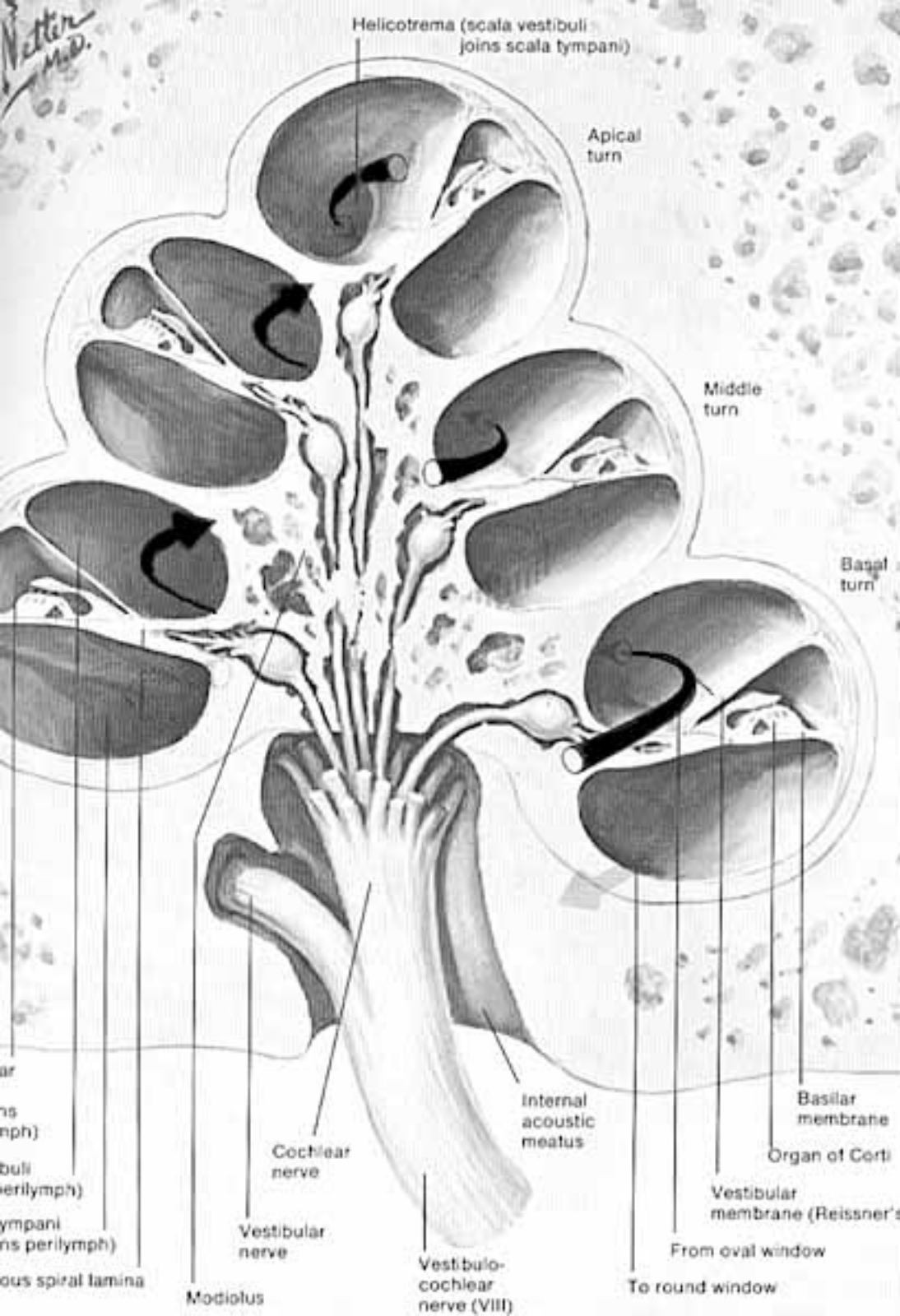
Helicotrema (scala vestibuli joins scala tympani)
Apical turn
Middle turn
Basal turn
Internal acoustic meatus
Basilar membrane
Organ of Corti
Vestibular membrane (Reissner's
From oval window
To round window
Cochlear nerve
Vestibular nerve
Vestibulo-cochlear nerve (VIII)
Modiolus
ous spiral lamina

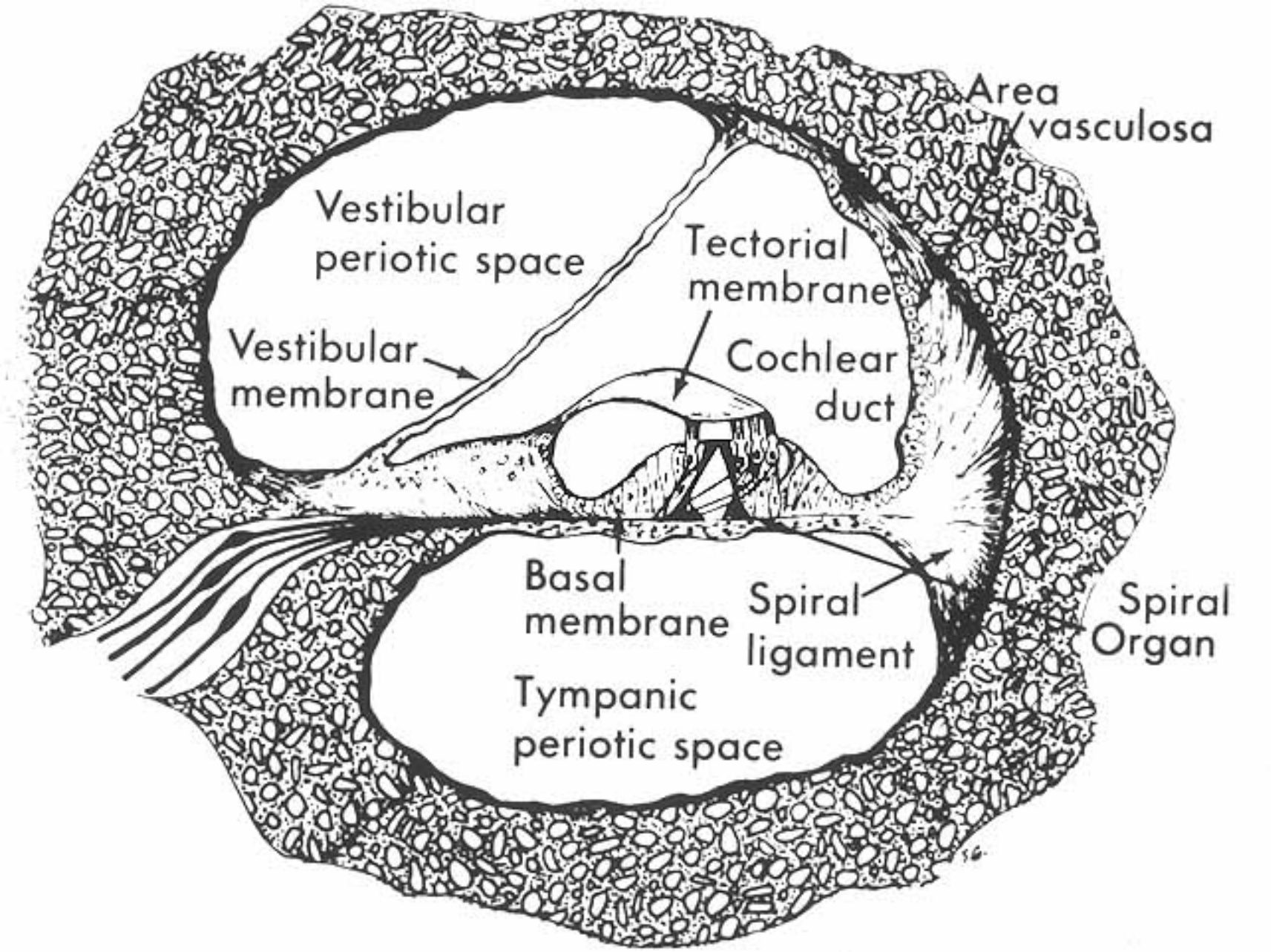
Area vasculosa
Vestibular periotic space
Tectorial membrane
Vestibular membrane
Cochlear duct
Basal membrane
Spiral ligament
Spiral Organ
Tympanic periotic space

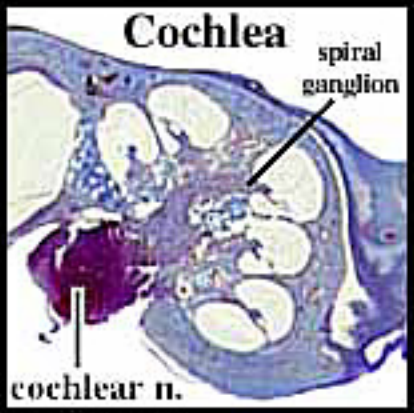
Cochlea
spiral ganglion
cochlear n.

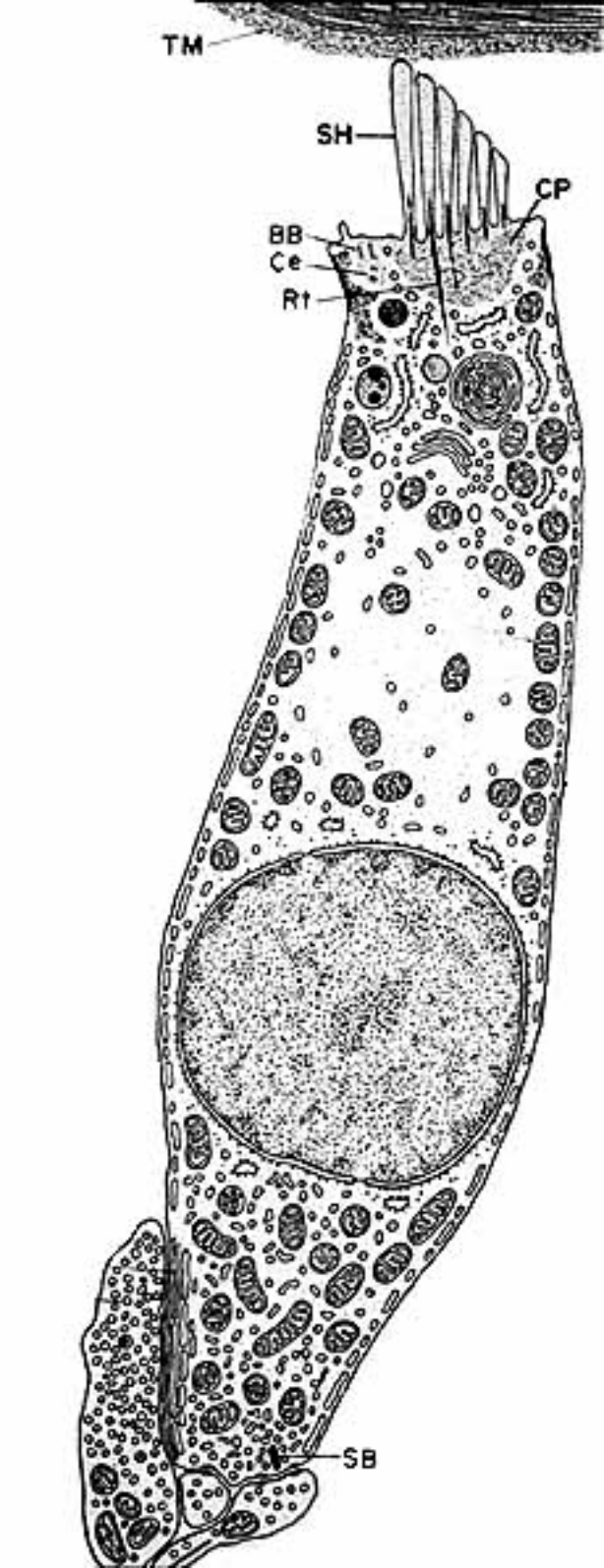
TM
SH
CP
BB
Ce
Rt
SB

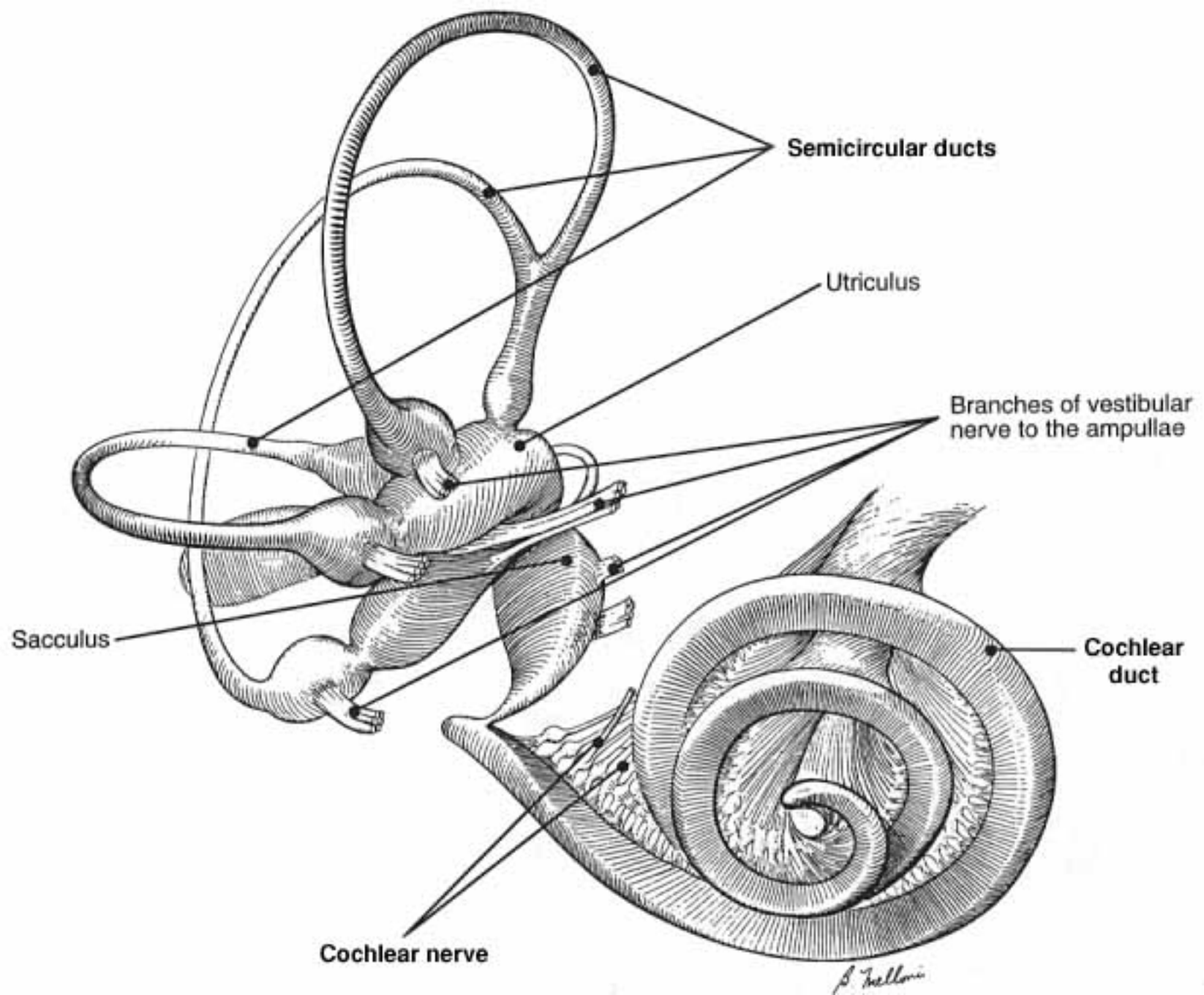
Semicircular ducts
Utriculus
Branches of vestibular nerve to the ampullae
Sacculus
Cochlear duct
Cochlear nerve

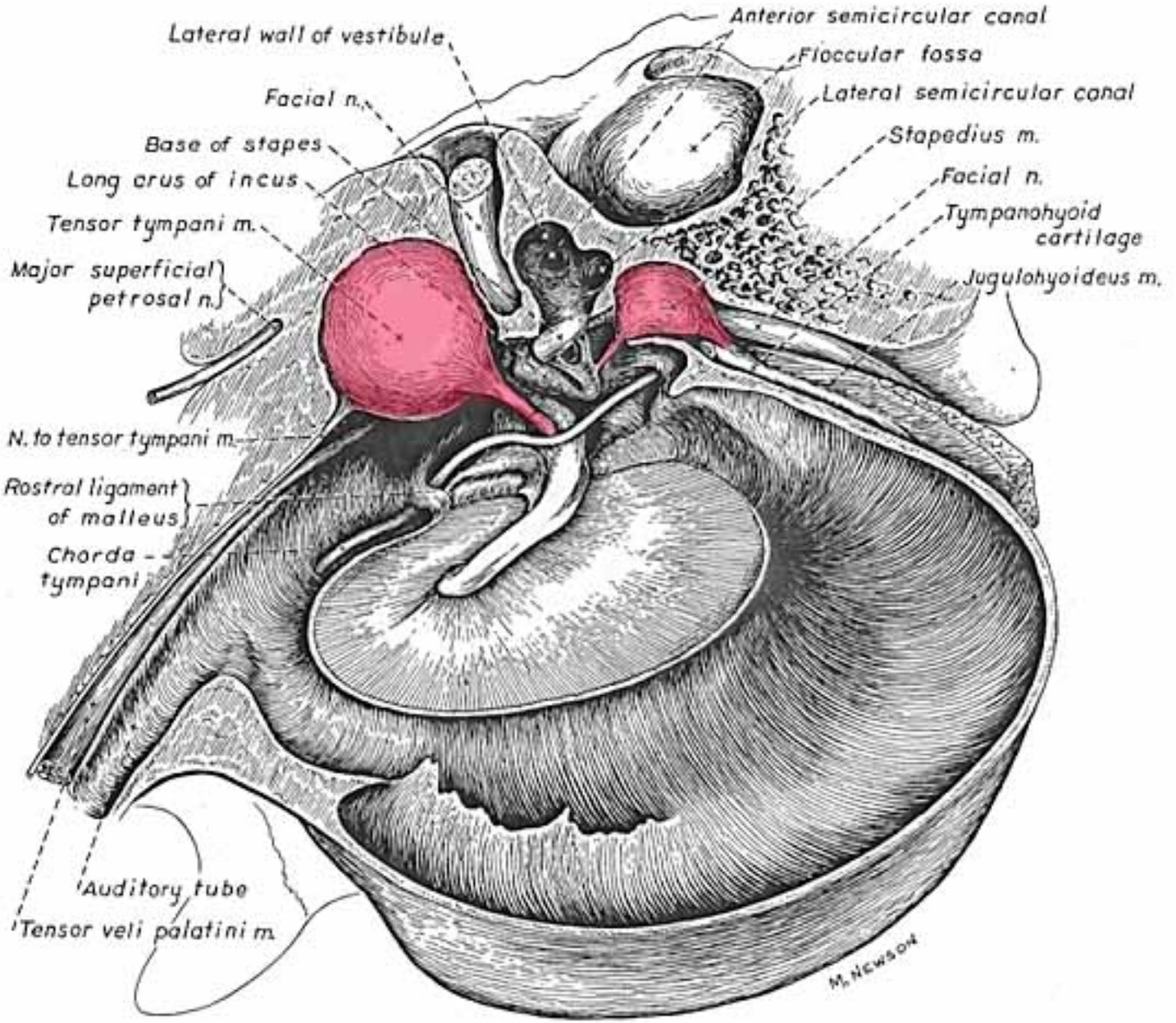
Lateral wall of vestibule
Facial n.
Base of stapes
Long crus of incus
Tensor tympani m.
Major superficial petrosal n.
N. to tensor tympani m.
Rostral ligament of malleus
Chorda tympani
Auditory tube
Tensor veli palatini m.
Anterior semicircular canal
Flocculer fossa
Lateral semicircular canal
Stapedius m.
Facial n.
Tympanohyoid cartilage
Jugulohyoideus m.
M. NEWSON

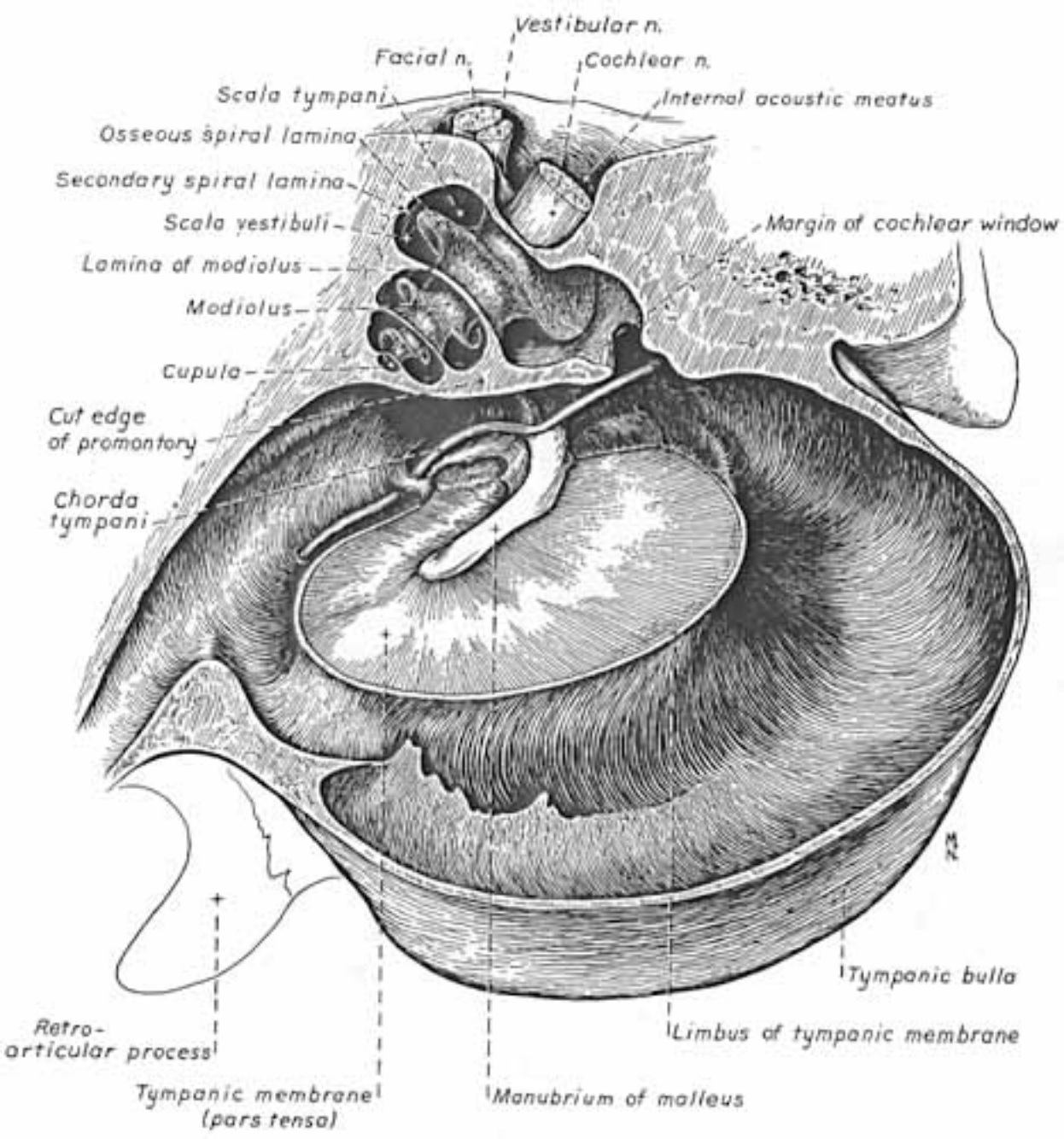
Vestibular n.
Facial n.
Cochlear n.
Scala tympani
Internal acoustic meatus
Osseous spiral lamina
Secondary spiral lamina
Scala vestibuli
Margin of cochlear window
Lamina of modiolus
Modiolus
Cupula
Cut edge of promontory
Chorda tympani
Tympanic bulla
Retro-articular process
Limbus of tympanic membrane
Tympanic membrane (pars tensa)
Manubrium of malleus

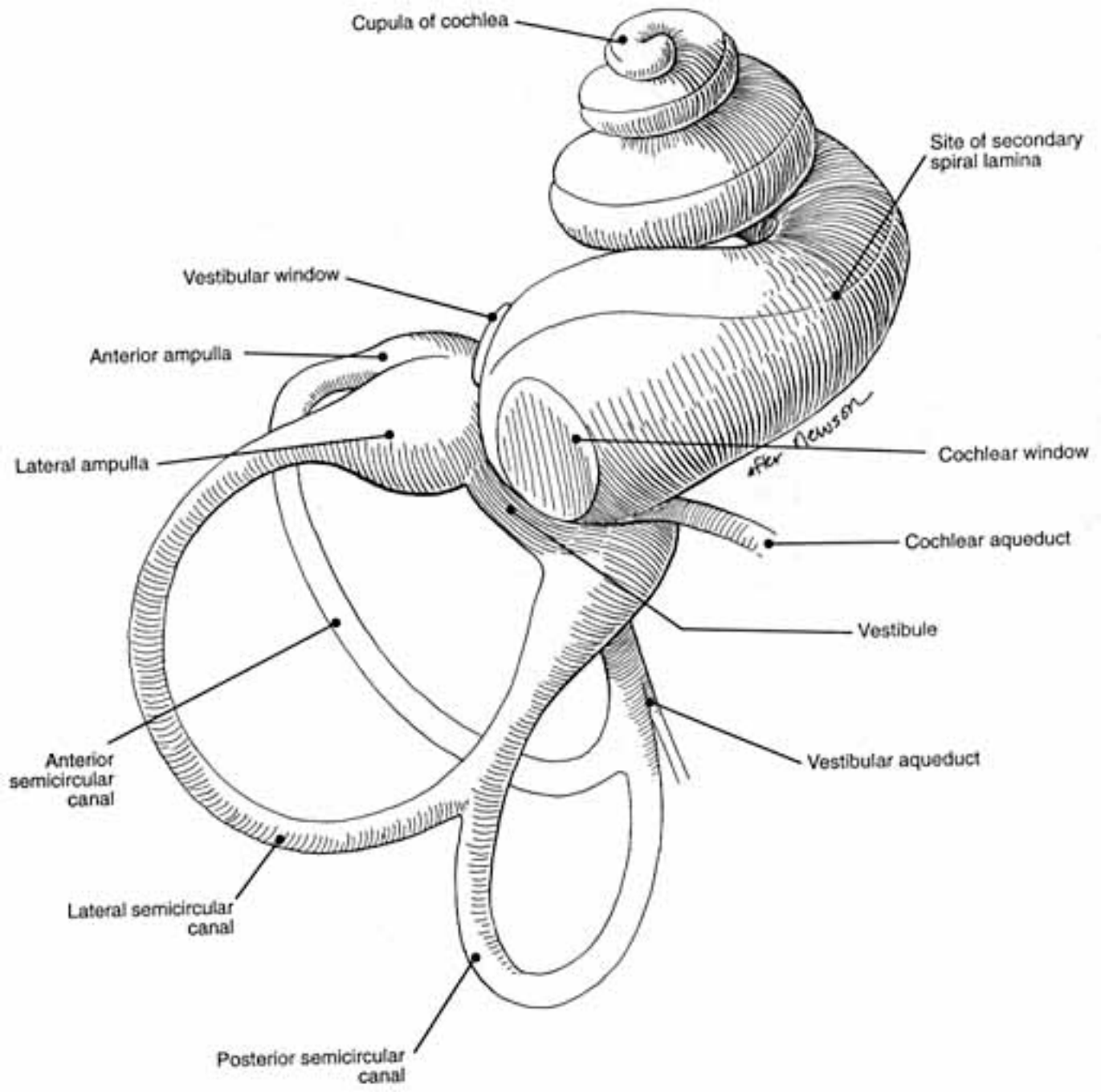
Cupula of cochlea
Site of secondary spiral lamina
Vestibular window
Anterior ampulla
Lateral ampulla
Cochlear window
Cochlear aqueduct
Vestibule
Anterior semicircular canal
Vestibular aqueduct
Lateral semicircular canal
Posterior semicircular canal

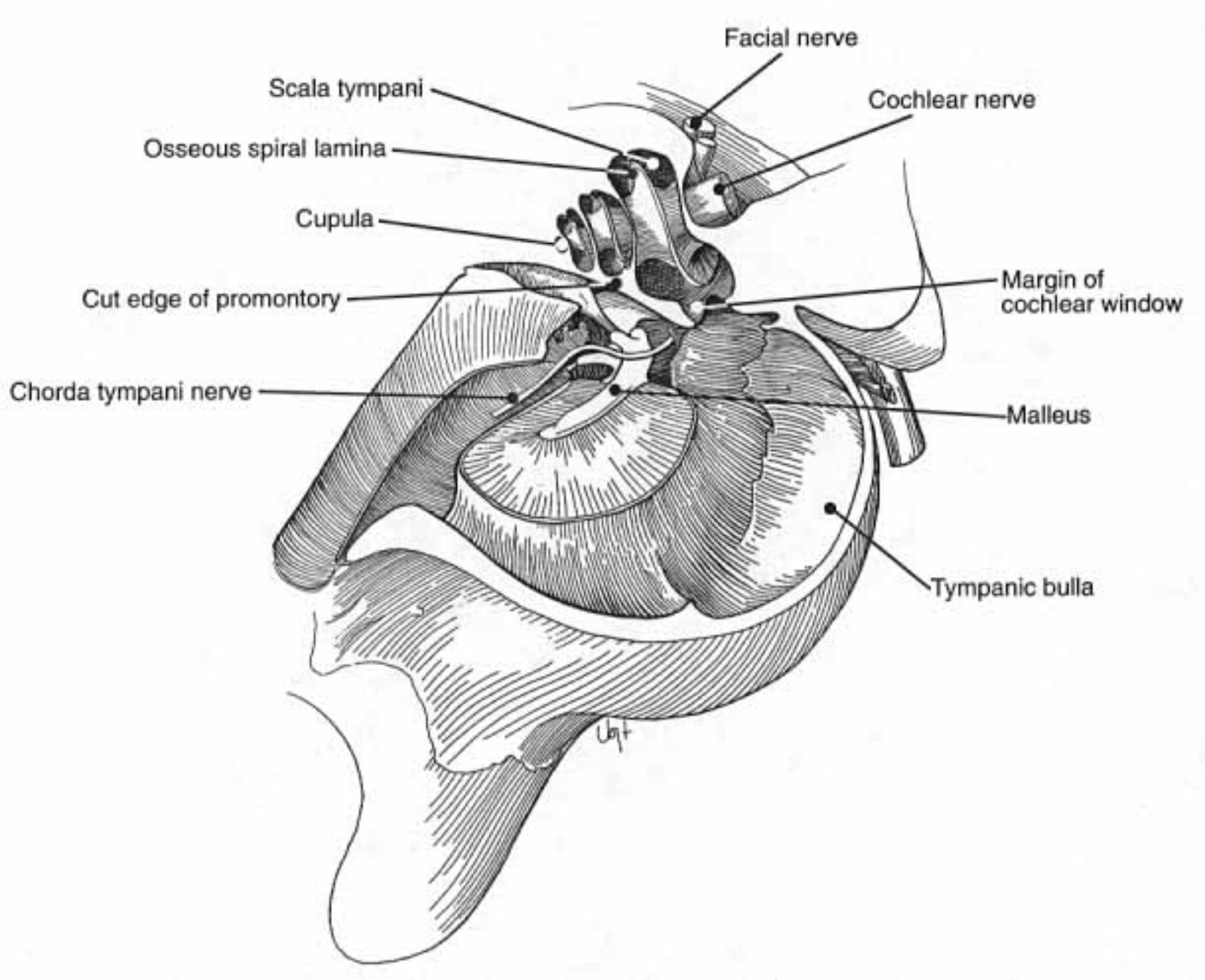
Facial nerve
Scala tympani
Cochlear nerve
Osseous spiral lamina
Cupula
Cut edge of promontory
Margin of cochlear window
Chorda tympani nerve
Malleus
Tympanic bulla